

*"Well, I slur the 'ph' and the 'th' and some of the harsh sounds. And they come real slurred, almost like I was drunk . . . and it's like I can't control my lips and tongue, and they'll occasionally get in my way. I know this could be carelessness, but it very seldom used to happen. Now it happens quite often!"*

*(62-year-old man with degenerative cerebellar disease and ataxic dysarthria)*

## CHAPTER OUTLINE

- I. Anatomy and basic functions of the cerebellar control circuit
- II. Localization of speech within the cerebellum
- III. Clinical characteristics of cerebellar lesions and ataxia
- IV. Etiologies
  - A. Degenerative diseases
  - B. Vascular disorders
  - C. Neoplastic disorders
  - D. Trauma
  - E. Toxic or metabolic conditions
  - F. Other causes
- V. Speech pathology
  - A. Distribution of etiologies, lesions, and severity in clinical practice
  - B. Patient perceptions and complaints
  - C. Clinical findings
  - D. Acoustic and physiologic findings
- VI. Cases
- VII. Summary

Ataxic dysarthria is a perceptually distinctive motor speech disorder (MSD) associated with damage to the cerebellar control circuit. It may be manifest in any or all of the respiratory, phonatory, resonatory, and articulatory levels of speech, but *its characteristics are most evident in articulation and prosody*. The disorder reflects the effects of incoordination and reduced muscle tone, the products of which are slowness and inaccuracy in the force, range, timing, and direction of speech movements. Ataxia is an important contributor to the speech deficits of

patients with cerebellar disease, hence the disorder's designation *ataxic* dysarthria. The identification of a dysarthria as ataxic can aid the diagnosis of neurologic disease and its localization to the cerebellum or cerebellar control circuit.

Ataxic dysarthria is encountered as the primary speech pathology in a large medical practice at a rate comparable to that for most other major single dysarthria types. Based on data for primary communication disorder diagnoses within the Mayo Clinic Speech Pathology practice, it accounts for 10.8% of all dysarthrias and 9.9% of all MSDs (see Figure 1-3).

The clinical features of ataxic dysarthria illustrate the important role of the cerebellum and its connections in speech motor control. Of all the individual dysarthria types, it most clearly reflects a breakdown in timing and coordination. When one listens to the speech of a person with ataxic dysarthria, the impression is not one of underlying weakness, resistance to movement, or restriction of movement, but rather one of an activity that is poorly timed and coordinated.

## ■ ANATOMY AND BASIC FUNCTIONS OF THE CEREBELLAR CONTROL CIRCUIT

The cerebellar control circuit consists of the cerebellum and its connections. Its components are described in detail in Chapter 2. Here its structures, pathways, and functions that are most relevant to speech are briefly summarized.

The vermis forms the midportion of the anterior and posterior lobes of the cerebellum. To the sides of the vermis are the right and left cerebellar hemispheres, each of which is connected to the opposite thalamus and cerebral hemisphere. Each cerebellar

hemisphere is involved in controlling movement on the ipsilateral side of the body. Thus the left cerebral and right cerebellar hemispheres cooperate in coordinating movement on the right side of the body, and the right cerebral and left cerebellar hemispheres cooperate in coordinating movement on the left side of the body. The lateral cerebellar hemispheres are particularly important to the coordination of skilled voluntary muscle activity and tone.

*Purkinje cells*, whose functions are inhibitory, are the sole output neurons of the cerebellar cortex. They synapse with deep cerebellar nuclei, and their output departs the cerebellum through the superior and inferior cerebellar peduncles.

The cerebellum influences and is informed about activities at several levels of the motor system. The primary and essential connections for its role in speech control include: (1) reciprocal connections with the cerebral cortex; (2) auditory and proprioceptive feedback from speech muscles, tendons, and joints; (3) reciprocal connections with brainstem components of the indirect activation pathway; and (4) cooperation with the basal ganglia control circuit through loops among the thalamus, cerebral cortex, and components of the indirect motor system.

From a functional standpoint, *the cerebellum helps time the components of movement, scale the size of muscle actions, and coordinate sequences of muscle contractions for skilled motor behavior.*<sup>20,31,68</sup> It presumably receives notice of intended movements from the cerebral cortex and monitors the adequacy of movement outcomes based on feedback from muscles, tendons, and joints. It can influence subsequent cortical motor output based on that feedback and on ongoing information from the cortex about upcoming movement goals. This permits it to make modifications that smooth the timing and coordination of movement.

### LOCALIZATION OF SPEECH WITHIN THE CEREBELLUM

The localization of speech within the cerebellum is uncertain. Brown, Darley, and Aronson,<sup>23</sup> examining disparities in gait, limb, and speech disturbances in people with cerebellar disease, concluded that areas other than the anterior portion of the vermis are probably important or sufficient for motor speech control. They also concluded that ataxic dysarthria usually results from bilateral or generalized cerebellar disease, even though it may sometimes be due to a more focal lesion.

Where are such focal lesions? Chiu, Chen, and Tseng,<sup>25</sup> examining 15 patients with cerebellar disease and dysarthria, concluded that midline structures and the vermis and fastigial nucleus were the primary locus for coordination of speech. Ackermann et al.<sup>8</sup> concluded that ataxic dysarthria is

especially associated with damage to paramedian regions of the superior cerebellar hemispheres, that lesions in the dentate nucleus are linked to phonatory disturbances, and that the most severe articulatory deficits are associated with bilateral lesions. Several studies of people with cerebellar tumors or small cerebellar infarcts implicate the paravermal areas and lateral cerebellar hemispheres.<sup>8,12,13,69</sup> Kent et al.,<sup>64</sup> noting that lesions generally include vermal and paravermal areas, as well as the lateral cerebellar hemispheres, concluded, "Possibly, different parts of the cerebellum are involved in motor control of different motor systems within speech production, or they are involved with different functions of motor control." In general, therefore, *ataxic dysarthria is most commonly associated with bilateral or generalized cerebellar disease. When lesions in the cerebellum are focal, the lateral hemispheres and posteromedial or paravermal regions are implicated.*

Lesions causing ataxic speech may not be confined to the cerebellum. Clinical evidence indicates that it also can result from lesions to the superior cerebellar peduncle or anywhere along the frontopontocerebellar pathways.<sup>64,98</sup>

Might speech functions be lateralized within the cerebellum, similar to the lateralization of speech and language within the cerebral hemispheres? Holmes<sup>51</sup> observed that disease affecting only one lateral cerebellar hemisphere could affect speech, but that speech usually improves rapidly when lesions are unilateral. Lechtenberg and Gilman<sup>69</sup> observed that dysarthria in 31 patients with nondegenerative cerebellar dysarthria was much more common when the disease was exclusively or predominantly in the left cerebellar hemisphere than when it was exclusively or predominantly in the right cerebellar hemisphere or vermis. Because prosodic disturbances are prominent in ataxic dysarthria, they felt that the "dominance" of the left cerebellar hemisphere is logically related to its strong ties to the right cerebral hemisphere and its apparently important role in prosodic functions. In contrast, however, Ackermann et al.<sup>8</sup> reported that three of their four patients with dysarthria resulting from unilateral cerebellar strokes had right-sided lesions. Also, Gironell, Arboix, and Marti-Vilalta<sup>44</sup> reported a case with dysarthria from a right-sided paravermal stroke and argued that the superior right paravermal zone might be the "cerebellar speech centre."<sup>\*</sup>

\*Kent and Rosenbek<sup>64</sup> have discussed the relationship of cerebellar functions to speech prosody, and the relationship of prosodic disturbances in cerebellar disease to the aprosody and dysprosody that may occur with right and left cerebral hemisphere lesions, respectively. They said, "We should not conclude that the cerebellum is normally a generator of prosody. It may instead be part of a larger neuronal circuit that regulates the prosodic base of speech."

The notion of lateralized cerebellar dominance, or different speech roles for the right versus left cerebellar hemispheres, is certainly relevant to our understanding of speech motor control. That there may be an asymmetric distribution of cerebellar lesions that lead to ataxic dysarthria also raises the possibility of different "types" of ataxic dysarthria that are dependent upon the lateralization of cerebellar lesions. It should be noted, however, that ataxic dysarthria is not just a prosodic disturbance (articulation, at the least, is also affected), and that several other dysarthria types (and aprosodia and apraxia of speech) also affect prosody, although in a manner distinguishable from that resulting from cerebellar lesions. In addition, Kent et al.<sup>64</sup> note that a full understanding of cerebellar localization for speech must account for remote effects of lesions as well as local effects. For example, one consequence of cerebellar disease seems to be a diminished facilitatory influence of the cerebellum on the motor cortex of the cerebral hemispheres.<sup>71</sup> Finally, as Gilman, Bloedel, and Lechtenberg<sup>42</sup> state, "It is unlikely that only one cerebellar locus could be responsible for all of the facets of speech disorder occurring with cerebellar disease." Thus at this point, caution should be exercised in drawing conclusions about the lateralization of speech functions within the cerebellum.

#### █ CLINICAL CHARACTERISTICS OF CEREBELLAR LESIONS AND ATAXIA

Difficulties with standing and walking are the most common signs of cerebellar disease, and gait is often referred to as *ataxic*. Stance and gait are usually broad based, and truncal instability may lead to falls. Steps may be irregularly placed, and the legs lifted too high and slapped to the ground. There may be no difference in steadiness when standing with the feet together with the eyes open versus closed (*Romberg test*).

*Titubation* is a rhythmic tremor of the body or head that can occur with cerebellar disease. It is usually manifest as rocking of the trunk or head forward or back, side to side, or in a rotary motion, several times per second.

The most common of the abnormal eye movements that can occur in cerebellar disease is *nystagmus*, which is characterized by rapid oscillation or back and forth jerky movements of the eyes at rest or with lateral or upward gaze. Patients may also exhibit *ocular dysmetria*, in which small, rapid eye movements develop as they attempt to fix on a visual target and attempt to correct for inaccurate fixation.

*Hypotonia*, a decrease in resistance to passive movement, can occur in cerebellar disease. It can be associated with excessive *pendulousness*, in which

an extremity, allowed to swing freely in a pendular manner, has a greater than average number of oscillations before coming to rest; this is a function of decreased muscle tone or decreased resistance to movement. A related phenomenon, known as *impaired check and excessive rebound*, can also occur. For example, when asked to maintain the arm in an outstretched position with the eyes shut, a light tap on the wrist results in a large displacement of the limb followed by overshoot beyond the original position when it returns. The wide excursion reflects impaired check, whereas overshoot reflects excessive rebound.

*Dysmetria*, a common sign of cerebellar disease, is a disturbance in the trajectory of a body part during movement or an inability to control range of movement. It is often characterized by overshooting or undershooting of targets, as well as by abnormalities in speed, giving movements an irregular appearance. It is frequently detected when patients are asked to repetitively touch the tip of their index finger to their nose and then to fully extend the arm to touch the examiner's finger (nose-finger-nose test).<sup>78</sup>

*Dysdiadokokinesia* is a manifestation of *decomposition of movement (dyssynergia)*, which refers to errors in the sequence and speed of component parts of a movement, with a resultant lack of coordination. It can be elicited by testing alternating repetitive movements. A common task is the *knee-pat test* in which the patient pats the knee alternately with the palm and dorsum of the hand, gradually increasing to a maximum rate; side-to-side tongue wiggling and patting the floor with the ball of the foot are examples of other alternate motion rate (AMR) tasks used to elicit dysdiadokokinesia. Poor performance on such tasks is characterized by abnormalities in rate, rhythm, amplitude, and precision. Speech AMRs are analogous to these tests of coordination and speed.

*Ataxia is the product of dysmetria, dysdiadokokinesia, and decomposition of movement.* Ataxic movements are halting, imprecise, jerky, poorly coordinated, and lacking in speed and fluidity or smoothness. Ataxia is generally associated with disease of the cerebellar hemispheres.\*

Cerebellar disease is sometimes associated with *intention or kinetic tremor* that is apparent during movement or sustained postures and is usually most obvious as a target is approximated (*terminal tremor*). This cerebellar tremor usually occurs with disorders of the lateral cerebellar hemispheres.

Some signs that occur in conjunction with cerebellar disease do not reflect cerebellar dysfunction

\*The relevance of dysarthria to the diagnosis and quantification of ataxia and cerebellar syndromes is reflected in its inclusion as one of four major symptom categories in the International Co-operative Ataxia Rating Scale.<sup>97</sup>

per se. Mild facial weakness, often limited to the lower face, occurs frequently with focal cerebellar lesions, more often with cerebellar hemisphere than midline lesions.<sup>42</sup> Although pressure effects on cranial nerve VII are a possible explanation, there may be other, as yet undetermined, explanations. Abnormalities of cranial nerves V, VI, and VIII may also be encountered.

Finally, *cognitive disturbances may be present*. Cognitive deficits encountered in people with cerebellar disease traditionally have been discounted as an artifact of accompanying noncerebellar deficits. However, recent clinical observations and functional neuroimaging studies suggest that the cerebellum contributes to a number of cognitive functions, including language processing, that are not necessarily related to motor activities.<sup>58,77,81</sup> In the author's experience, the content, organization, and pragmatics of verbal statements made by some people with ataxic dysarthria and what appear to be isolated cerebellar deficits are not quite normal. These abnormalities seem more akin to nonaphasic cognitive-communication deficits than to aphasic language impairments.

## ETIOLOGIES

Any process that damages the cerebellum or cerebellar control circuit can cause ataxic dysarthria. These processes include degenerative, demyelinating, vascular, neoplastic, inflammatory, traumatic, and toxic

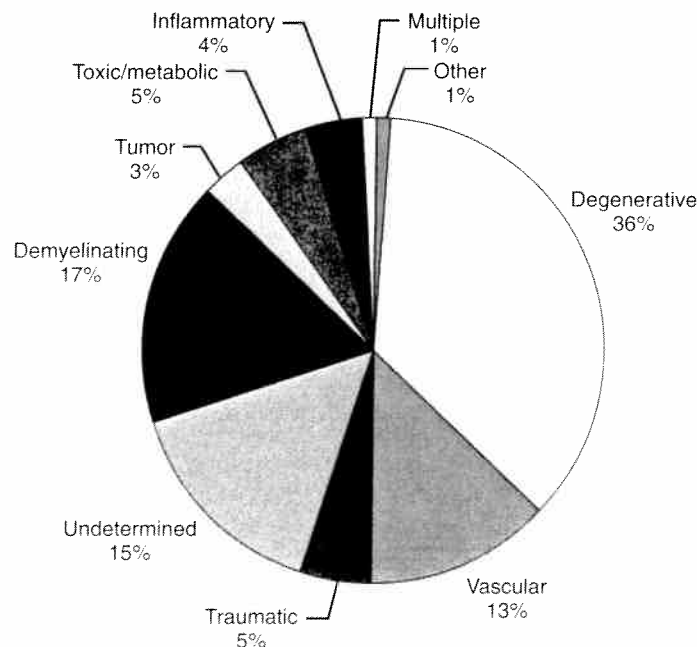
or metabolic diseases. These etiologic categories are associated with ataxic dysarthria with varying frequency. The exact distribution of causes of ataxic dysarthria is unknown, but degenerative, demyelinating, and vascular diseases seem to be the most frequent known causes (see Figure 6-1 and Box 6-1).

The presence of ataxic dysarthria, by itself, is not diagnostic of any specific neurologic disease. However, several diseases are associated with ataxic dysarthria more frequently than with other dysarthria types. In addition, some diseases specifically affect the cerebellum and are uniquely associated with ataxic dysarthria. Some common neurologic conditions that are associated with ataxic dysarthria more frequently than with other dysarthria types are discussed as follows. Other diseases that can produce it but are more frequently associated with other dysarthria types (especially mixed dysarthrias) are discussed in the chapters that address those specific dysarthrias.

## Degenerative Diseases

Degenerative diseases that affect the cerebellum are not uncommon. Their mechanisms are generally poorly understood, but an increasing number seem to have a hereditary basis.

The most common and well-characterized *hereditary ataxias* may be autosomal dominant or autosomal recessive; X-linked forms have been described



**FIGURE 6-1** Distribution of etiologies for 166 quasirandomly selected cases with a primary speech pathology diagnosis of ataxic dysarthria at the Mayo Clinic from 1969-90 and 1999-2001 (see Box 6-1 for details).

Etiologies for 166 quasirandomly selected cases with a primary speech pathology diagnosis of ataxic dysarthria at the Mayo Clinic from 1969-1990 and 1999-2001. Percentage of cases for each etiology is given in parentheses. Specific etiologies under each heading are ordered from most to least frequent.

#### Degenerative (35%)

Cerebellar degeneration, unspecified etiology (14%)  
 OPCA (5%)  
 Shy-Drager syndrome (2%)  
 Multiple systems atrophy (2%)  
 Cerebellar atrophy, hereditary (1%)  
 Other (10%)  
 Cerebellar and brainstem degeneration; PSP; Friedreich's ataxia; spinocerebellar degeneration; degenerative CNS disease; corticocerebellar degeneration; hereditary cerebral calcinosis

#### Demyelinating (17%)

Multiple sclerosis (16%)  
 Unspecified demyelinating disease (1%)

#### Undetermined (15%)

Undetermined cerebellar ataxia (4%)  
 Undetermined cerebellar atrophy (2%)  
 Other (9%)  
 Dysarthria only; paroxysmal periodic ataxia; undetermined cerebellar and brainstem disease; undetermined cerebellar lesion; Wilson's disease vs. liver disease; encephalitis vs. undetermined brainstem disease; tumor vs. AVM; undetermined neurologic problem

#### Vascular (13%)

Nonhemorrhagic stroke (single or multiple) (9%)  
 Hemorrhagic stroke (2%)  
 Other (2%)  
 Ruptured aneurysm, lupus, intracranial arteritis, anoxia

#### Toxic or Metabolic (5%)

Prescribed medication (anticonvulsants, lithium) (3%)  
 Other (2%)  
 Alcohol or drug abuse; anoxic encephalopathy associated with intentional drug overdose

#### Traumatic (5%)

Closed head injury (3%)  
 Penetrating head injury (1%)  
 Postoperative (1%)

#### Inflammatory (4%)

Encephalitis (2%)  
 Meningitis (1%)  
 Multifocal leukoencephalopathy (1%)

#### Tumor (3%)

Paraneoplastic syndrome, brainstem tumor, cerebello-pontine angle tumor

#### Multiple (1%)

Stroke + ? CNS degenerative disease

#### Other (1%)

Depression or personality disorder, hypothyroidism

AVM, Arteriovenous malformation; CNS, central nervous system; OPCA, olivopontocerebellar atrophy; PSP, progressive supranuclear palsy.

but are uncommon and not well characterized. Hereditary ataxias can be fatal or nonfatal and can begin in childhood or adulthood. They usually evolve over several decades. Some are largely confined to the cerebellum. When they also affect spinal cord tracts they are called *spinocerebellar*, and when they also affect the inferior olive and pontine nuclei they are called *olivopontocerebellar*.

Various *hereditary spinocerebellar ataxias (SCAs)* have overlapping phenotypes, but molecular genetics has permitted increasingly definitive molecular classification. Many recessively inherited ataxias produce initial symptoms in childhood. *Friedreich's ataxia* is the most common, with a prevalence of 1 in 50,000 persons. It usually begins before age 20 and it evolves to incapacitation and death over a course of approximately 20 years. Its cardinal features include limb and gait ataxia, dysarthria, absent muscle stretch reflexes in the

lower limbs, sensory loss, and signs of corticospinal tract involvement.<sup>36</sup> LMN weakness, as well as dystonia, chorea, and other movement disorders, may also occur. Several studies have examined the dysarthria associated with the disorder,<sup>39,43,54,84</sup> each describing speech characteristics consistent with ataxic dysarthria. Some imply that the dysarthria is mixed in character, with ataxic and spastic components.<sup>54,84</sup> Because the disease can affect portions of the motor system beyond the cerebellum, it is not surprising that its associated dysarthria is not always only ataxic in character.

*Ataxia telangiectasia\** is another progressive autosomal recessive disorder in which dysarthria is a frequent neurologic manifestation; truncal

\*Telangiectasia involves dilatation of capillary vessels and minute arteries.

or appendicular ataxia, choreoathetosis, dystonia, sensory loss, and distal muscle atrophy are among additional neurologic signs. The dysarthria has not been well described, but ataxic and mixed dysarthrias (ataxic, hyperkinetic, or flaccid) are logical possibilities. Dysarthria has also been reported in autosomal recessive *ataxia with isolated vitamin E deficiency*, a treatable disorder that emerges in childhood or adolescence and can resemble the Friedreich's ataxia phenotype.<sup>36</sup>

Dominantly inherited cerebellar ataxias have an estimated incidence in the general population of 5 in 100,000.<sup>36</sup> They tend to begin between 20 and 40 years of age. The terminology used to describe their genotype uses SCA types, such as SCA-1 and SCA-2. A recent review of hereditary ataxias<sup>36</sup> indicates that dysarthria is a characteristic of many SCA types that have been described. Their clinical features suggest that ataxic dysarthria should be a predominant dysarthria type, but, because multiple portions of the motor system can be involved in many SCAs, nearly any type seems logically possible. Finally, *episodic (or paroxysmal) ataxias* are uncommon, usually autosomal dominant conditions in which intermittent, brief attacks (seconds to minutes) of ataxia and dysarthria (presumably ataxic) occur, sometimes with other neurologic signs (e.g., myokymia, diplopia, nystagmus, vertigo). Their recognition is important, because they may be effectively treated pharmacologically, often with acetazolamide.<sup>36</sup>

*Olivopontocerebellar atrophy (OPCA)* is a degenerative disease that can be hereditary or sporadic. It is a heterogeneous condition associated with neurologic diseases that are broadly grouped under the heading of *multiple systems atrophy (MSA)*.<sup>90</sup> OPCA is associated with degeneration of the pontine, arcuate, and olivary nuclei, the middle cerebellar peduncles, and the cerebellum. It can also be associated with degenerative changes in the basal ganglia, cerebral cortex, spinal cord, and even peripheral nerves. The clinical features are variable, but cerebellar findings are the most common. Parkinsonism, movement disorders, pyramidal and ophthalmologic signs, bulbar and pseudobulbar palsy, and dementia can also occur.<sup>47</sup>

*Multiple sclerosis (MS)*, a demyelinating disease, may cause cerebellar lesions and ataxic dysarthria. Discussion of MS is deferred to Chapter 10, because MS lesions often are not confined to the cerebellum. However, a condition associated with MS, known as *paroxysmal ataxic dysarthria (PAD)*, deserves mention here, because its occurrence may be sug-

gestive of MS<sup>35</sup> or episodic ataxia, as described previously. In PAD, brief episodes of ataxic dysarthria occur in an individual whose speech may be otherwise normal. Netsell and Kent<sup>85</sup> reviewed 10 cases in the literature and 3 cases of their own with PAD and an established or provisional diagnosis of MS. The group's distinctive characteristics included: (1) a few to several hundred episodes per day, each lasting 5 to 30 seconds; (2) speech characteristics consistent with those of ataxic dysarthria; (3) the possibility of remission and reappearance at a later time, with or without new symptoms; (4) no evidence of associated seizures; (5) overbreathing sometimes evoked the paroxysms; (6) the paroxysms remitted in each case with administration of carbamazepine (Tegretol).

### Vascular Disorders

Vascular lesions can affect cerebellar function. Lesions are most commonly caused by aneurysms, arteriovenous malformations (AVMs), cerebellar hemorrhage, or stroke within the vertebrobasilar system. The lateral regions of the vertebrobasilar system, including the posterior inferior cerebellar artery (PICA) at the level of the medulla, the anterior inferior cerebellar artery (AICA) at the level of the pons, and the superior cerebellar artery at the level of the midbrain, are most often implicated in cerebellar and superior cerebellar peduncle lesions that lead to ataxic dysarthria.<sup>21,34,44</sup> Ataxic dysarthria may be more common with superior cerebellar artery than with PICA or AICA distribution lesions.<sup>18</sup>

*Von-Hippel Lindau disease* is an inherited autosomal dominant condition characterized by hemangioblastomas\* of the cerebellum and retina, as well as visceral cysts and tumors. The cerebellar tumors are usually removed surgically, but recurrence is possible. The tumors can also occur in the medulla and spinal cord and infrequently in the cerebral hemispheres. Diagnosis is usually made after the second decade.<sup>93</sup>

### Neoplastic Disorders

Tumors within the cerebellum or that exert mass effects on it can lead to cerebellar signs, including ataxic dysarthria. Cerebellopontine angle tumors, which often arise from the meninges (meningiomas) or supporting cells of cranial nerves, can lead to

\*A hemangioma is a benign, slow-growing tumor made up of newly formed blood vessels. A hemangioblastoma is a capillary hemangioma of the brain that consists of proliferated blood vessels or angioblasts (blood cells and vessels are derived from angioblasts).

\*MSA is discussed further in Chapter 10.

early cerebellar signs because of pressure on the middle cerebellar peduncle, dentate nucleus, and posterior cerebellar lobes. There also may be involvement of multiple cranial nerves, including V, VI, VII, VIII, and X, plus other signs of brainstem dysfunction.<sup>21</sup> Such tumors can lead to ataxic dysarthria, as well as to flaccid and spastic dysarthria.

Some posterior fossa tumors, particularly medulloblastomas and astrocytomas, are more common in children and young adults. They often arise in the midline and can displace portions of the cerebellum and sometimes infiltrate the cerebellar hemispheres.<sup>17</sup> Surgical intervention and subsequent radiation therapy can also impair cerebellar functions.

Sixteen percent of metastatic brain tumors develop in the cerebellum.<sup>52</sup> Signs and symptoms of cerebellar disease can be the first evidence that the patient has a tumor, the primary tumor remaining occult.

Neoplasm outside the central nervous system (CNS) is frequently suspected in patients with signs of nonfamilial cerebellar degeneration of late onset. This suspicion is fueled by the existence of *paraneoplastic disorders*, rare and intriguing autoimmune conditions associated with cancer. *Paraneoplastic cerebellar degeneration* is thought to be one of the most common CNS paraneoplastic syndromes. Affected people usually have carcinoma outside the CNS (usually ovarian or lung), but the neurologic disorder does not reflect actual metastatic invasion by tumor and often precedes actual clinical evidence of the primary tumor by weeks to years. The syndrome tends to emerge and progress over weeks to months. Purkinje cells are predominantly affected, and antibodies to Purkinje cells are often present. Along with nystagmus and ataxia of gait and limbs, dysarthria is a common and sometimes first clinical manifestation of paraneoplastic cerebellar disease.<sup>14,26</sup> Its type has been confirmed as ataxic or mixed ataxic-spastic.<sup>87</sup>

### Trauma

Traumatic brain injury (TBI) is frequently associated with limb ataxia and dysarthria.<sup>41,101,103</sup> Anoxia secondary to TBI is often invoked as the cause of cerebellar deficits, but damage to the superior cerebellar peduncles, which are vulnerable to the rotational injuries associated with TBI, has also been associated with cerebellar signs, including dysarthria.<sup>24</sup>

"Punch-drunk" *encephalopathy* or *dementia pugilistica* is often encountered in boxers who have sustained repeated cerebral injuries. The cerebellum is among the areas of the CNS that undergo pathologic changes,<sup>11</sup> and affected individuals can be ataxic and have ataxic dysarthria.

### Toxic or Metabolic Conditions

Acute and chronic alcohol abuse can produce cerebellar signs and symptoms, the most common of which are abnormal stance and gait. Cerebellar degeneration associated with alcoholism is well documented.<sup>16</sup> Although ataxic speech frequently occurs with acute alcohol intoxication, permanent dysarthria in chronic alcoholism is not common.<sup>42</sup>

Neurotoxic levels of several drugs can produce cerebellar signs and symptoms. These drugs include anticonvulsants, such as phenytoin (Dilantin), carbamazepine (Tegretol), valproic acid (Depakote), and primidone (Mysoline). Lithium, used to treat manic depressive illness, can produce sometimes-irreversible neurotoxic effects that include postural or intention tremor, ataxia, hyperkinesia, and dysarthria<sup>56,67</sup>; in the author's experience the dysarthria is often ataxic but sometimes spastic or hyperkinetic. Ataxic dysarthria has been reported as the initial sign of acute cerebellar toxicity in response to cytosine arabinoside (ara-C) for treatment of acute leukemia.<sup>33,66</sup> Valium, an antianxiety drug, has also been associated with ataxic dysarthria.<sup>82</sup> Finally, signs of cerebellar dysfunction can develop with severe malnutrition and vitamin deficiencies (e.g., thiamine, vitamin E).<sup>100</sup>

### Other Causes

*Hypothyroidism* is an endocrine disturbance caused by insufficient secretion of thyroxin by the thyroid glands. When severe (*myxedema*), it can lead to ataxic dysarthria.<sup>55</sup> It can be accompanied by a hoarse, gravelly, and excessively low-pitched dysphonia caused by mass loading of the vocal folds with myxomatous material.<sup>15</sup>

*Normal pressure hydrocephalus (NPH)* is a condition in which the ventricles may be enlarged while normal cerebrospinal fluid (CSF) pressure is maintained. It has been associated with trauma, subarachnoid hemorrhage, and meningitis, but etiology is often unclear. It is recognized by a triad of symptoms that include progressive gait disorder, impaired mental function, and urinary incontinence.<sup>92</sup> Dysarthria can occur in NPH and it can be ataxic in character.

Cerebellar signs and symptoms, including dysarthria, can occur as uncommon manifestations of heat stroke.<sup>76</sup> A number of viral, bacterial, and other infectious processes can lead to CNS disease with prominent cerebellar dysfunction in children and adults (e.g., rubella, Creutzfeldt-Jacob disease, Lyme disease, CNS tuberculosis).<sup>100</sup> Although uncommon, *Guillain-Barré syndrome*—usually associated with flaccid dysarthria—can sometimes be



characterized by ataxia and, subsequently, ataxic dysarthria. This variant of the disease is sometimes called *Fisher syndrome*.<sup>91</sup>

Finally, lack of proprioceptive input can lead to *sensory ataxia*, a problem that emerges in certain sensory neuropathies. Dysarthria has been reported in people with severe peripheral axonal loss that disproportionately affects sensory nerves.<sup>37</sup> The author has seen a small number of patients with known sensory neuropathy whose speech characteristics were consistent with those of ataxic dysarthria.

## ■ SPEECH PATHOLOGY

### Distribution of Etiologies, Lesions, and Severity in Clinical Practice

Box 6-1 and Figure 6-1 summarize the etiologies for 166 quasirandomly selected cases seen at the Mayo Clinic with a speech pathology diagnosis of ataxic dysarthria. The cautions expressed in Chapter 4 about generalizing these data to the general population or all speech pathology practices also apply here.

The data establish that ataxic dysarthria can result from a number of medical conditions. Ninety percent of the cases are accounted for by degenerative, demyelinating, vascular, toxic or metabolic, traumatic, and undetermined etiologies. Degenerative, demyelinating, and vascular diseases account for more than 65% of the cases.

Degenerative diseases were the most frequent cause (35%), with approximately 40% of them accounted for by relatively isolated cerebellar degenerative disease of undetermined etiology. The remainder of the degenerative etiologies included more specific entities such as OPCA, Shy-Drager syndrome, multiple systems atrophy, progressive supranuclear palsy (PSP), and cerebellar and brainstem degeneration. Most of these latter conditions are typically associated with degeneration that affects more than the cerebellum; consequently, they are often associated with other or additional dysarthria types. They are described more completely in Chapter 10. The remaining etiologies (Friedreich's ataxia and spinocerebellar degeneration) have already been defined.

MS accounted for nearly all of the demyelinating etiologies. Its 16% representation within the sample suggests that ataxic dysarthria is not uncommon in MS and may occur as the only dysarthria type in MS more frequently than other single dysarthria types (e.g., MS accounted for 4% of the cases of spastic dysarthria that were reviewed in Chapter 5). However, because lesions may be disseminated in many locations of the nervous system in MS, mixed

dysarthrias are common. MS is discussed in more detail in Chapter 10.

A substantial number of patients did not receive a definitive etiologic diagnosis. Within this group were patients with several possible diagnoses (e.g., tumor vs. AVM) plus a number whose symptoms and course were too subtle or short-lived to be understood. It is likely that some of these patients had degenerative cerebellar diseases and probable that a clearer diagnostic picture emerged as the disease progressed.

Nonhemorrhagic stroke accounted for most of the vascular causes. A majority of those with stroke had a single event, with the remainder having multiple strokes. Nearly half of the vascular cases had an identifiable lesion in the cerebellum. Most of the remaining cases had lesions in the brainstem or midbrain. It is likely that the ataxic dysarthria in these latter cases resulted from damage to major cerebellar pathways. For example, lesions of the superior cerebellar peduncles can lead to the same abnormalities that occur with cerebellar hemispheric lesions.<sup>98</sup> A few cases had supratentorial lesions (e.g., posterior right frontal lobe, multiple lesions in the periventricular white matter); whether the lesions in these cases were responsible for the ataxic dysarthria is a matter of conjecture, but they do support the notion that ataxic dysarthria can result from lesions anywhere along the corticocerebellar pathways (see Chapter 9 for further discussion of this possibility).

Toxic or metabolic causes for ataxic dysarthria are noteworthy, because they were not evident in the cases of flaccid or spastic dysarthria that were reviewed in Chapters 4 and 5. Most often, the ataxic dysarthria was secondary to anticonvulsant medications prescribed for epilepsy. Medication effects should always be suspected as a possible cause of ataxic dysarthria in individuals with seizure disorders who are on anticonvulsant medications.

The association of ataxic dysarthria with TBI in this sample is in general agreement with the observations of Yorkston et al.<sup>103</sup> TBI accounted for a somewhat smaller proportion of cases of ataxic dysarthria reviewed here than cases of spastic dysarthria reviewed in Chapter 5. This does not necessarily mean that isolated spastic dysarthria occurs more frequently than isolated ataxic dysarthria in the TBI population, because these cases were selected on the basis of dysarthria diagnosis and not on the basis of etiology.

The data also establish that ataxic dysarthria can occur in association with inflammatory disease, such as encephalitis and meningitis, demonstrating that focal deficits can occur in conditions that are often diffuse in nature. Tumors associated with ataxic dysarthria were relatively uncommon but were con-



sistently located in the cerebellum or adjacent to it (cerebellopontine angle) or affected cerebellar function indirectly (paraneoplastic syndrome).

Of those patients who had abnormalities detected by neuroimaging, approximately half had lesions or atrophy that were confined to or included the cerebellum; others had lesions more generally localized to the brainstem or posterior fossa. A significant minority had evidence of generalized, diffuse, or multifocal abnormalities. A few had evidence of cerebral hemisphere lesions without evidence of cerebellar or posterior fossa abnormalities. This latter finding obviously does not rule out cerebellar or brainstem lesions in such patients, but as already discussed, it raises the possibility that ataxic speech characteristics may occur in individuals with supratentorial lesions.

Because many causes of ataxic dysarthria in the sample defied detection by neuroimaging (e.g., degenerative, toxic, undetermined etiologies), clinical findings often had to be relied on for localization. In this regard, the great majority of the sample had nonspeech clinical signs of cerebellar involvement. In general, the clinical neurologic findings and neuroimaging data indicate that most patients with ataxic dysarthria have lesions or clinical signs that are localizable to the cerebellum or to the cerebellar pathways in the brainstem. This is reassuring, because the sample was selected on the basis of speech diagnosis and not localization of disease. Therefore the data generally confirm the localizing value of a diagnosis of ataxic dysarthria.

This retrospective review did not permit a precise description of dysarthria severity. However, in those patients for whom a judgment of intelligibility was stated (69% of the sample), 48% had reduced intelligibility. The degree to which this figure accurately estimates the frequency of intelligibility impairments in the population with ataxic dysarthria is unclear. It is likely that many patients for whom an observation of intelligibility was not made had normal intelligibility; however, the sample probably contains a larger number of mildly impaired patients than is encountered in a typical rehabilitation setting.

Finally, cognitive deficits were noted in 15% of the patients in the sample. The reasons for these deficits are uncertain, but they could reflect incidental problems stemming from abnormalities in non-cerebellar structures or direct or indirect effects of the cerebellar abnormalities themselves.

### Patient Perceptions and Complaints

People with ataxic dysarthria sometimes describe their speech in ways that provide clues to their speech diagnosis and its localization. Similar to those with other dysarthria types, they often complain that their speech is *slurred*. Unlike most

patients with other dysarthria types, however, they also often refer to the “*drunken*” quality of their speech, either as they perceive it (“I sound like I’m drunk”) or as others have commented upon it (“People ask me if I’ve been drinking”). They may also report dramatic deterioration in their speech with limited alcohol intake. They occasionally report an inability to coordinate their breathing with speaking and sometimes note that they bite their cheek or tongue while talking or eating. When the dysarthria is mild, they may comment that speech proceeds normally until they suddenly *stumble over words*. They may complain about the negative effects of fatigue on their speech, but perhaps less so than those with flaccid or spastic dysarthria. They do not often complain of exerting increased physical effort in speaking. They often report that slowing speech rate improves intelligibility.

Drooling is an uncommon complaint. Swallowing complaints are much less frequent than encountered with flaccid or spastic dysarthria, and they usually relate to the oral phase of swallowing. This is consistent with observations that the cerebellum does not play an important role in swallowing.<sup>75</sup>

### Clinical Findings

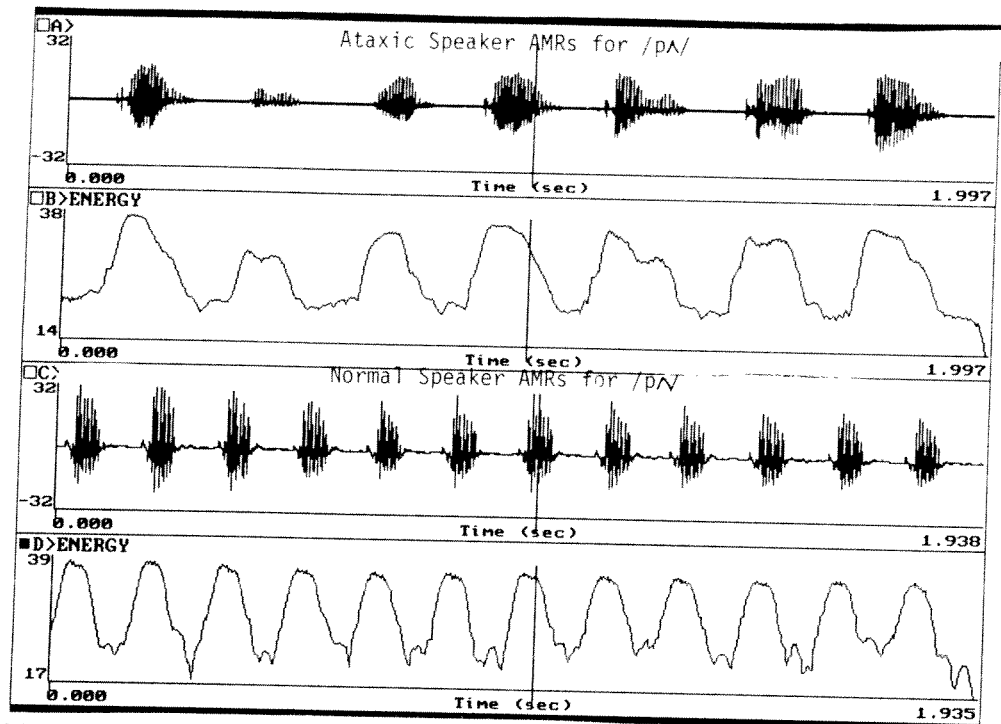
Ataxic dysarthria usually occurs with other signs of cerebellar disease, but sometimes it is the initial or only sign of cerebellar dysfunction.\* In such cases, recognition of the dysarthria as ataxic can be valuable to neurologic localization, especially because there may be no other oromotor evidence of neurologic disease.

### Nonspeech Oral Mechanism

The oral mechanism examination is often normal. That is, the size, strength, and symmetry of the jaw, face, tongue, and palate may be normal at rest, during emotional expression, and during sustained postures. The gag reflex is usually normal, and pathologic oral reflexes are absent. Drooling is uncommon, and the reflexive swallow is usually normal on casual observation.

Nonspeech AMRs of the jaw, lips, and tongue may be irregular. This is usually most apparent on lateral wiggling of the tongue or retraction and pursing of the lips; judgments that nonspeech AMRs are irregular should be interpreted cautiously, and only after observing many normal individuals, because normal performance is frequently somewhat irregular on these tasks. It is more relevant and

\*For example, Brown, Darley, and Aronson<sup>23</sup> noted that ataxic dysarthria was the initial symptom in 7 of their 30 patients with cerebellar disease.



**FIGURE 6-2** Raw waveform and energy tracings of speech alternate motion rates (AMRs) for /pʌ/ by a normal speaker (*bottom two panels*) and a speaker with ataxic dysarthria. The normal speaker's AMRs are normal in rate ( $\approx 6.5$  Hz) and are relatively regular in duration and amplitude. In contrast, the ataxic speaker's are slow ( $\approx 3.5$  Hz) and irregular in amplitude, syllable duration, and intersyllable interval; these latter attributes represent the acoustic correlates of perceived irregular AMRs.

valuable to observe the direction and smoothness of jaw and lip movements during connected speech and speech AMRs for evidence of dysmetria. Irregular movements during speech are often observable, are not frequently observed in normal speakers, and are more relevant to the speech diagnosis than non-speech AMRs.

### Speech

Conversational speech, reading, and speech AMRs are the most useful tasks for observing the salient and distinguishing characteristics of ataxic dysarthria. Repetition of sentences containing multisyllabic words (e.g., "My physician wrote out a prescription"; "The municipal judge sentenced the criminal") may promote distinctive, irregular articulatory breakdowns and prosodic abnormalities. Speech AMRs can be particularly revealing (see Figure 6-2). *Irregular speech AMRs are a distinguishing characteristic of ataxic dysarthria.*

Similar to spastic dysarthria, the deviant speech characteristics of ataxic dysarthria are not easily described by listing each cranial nerve and the speech characteristics associated with its abnormal function. Ataxic dysarthria is associated with impaired coordination of movement patterns rather

than with deficits in individual muscles, and it is the breakdown in coordination among simultaneous and sequenced movements that gives it its distinctive character. *It is predominantly an articulatory and prosodic disorder.*

Table 6-1 summarizes the neuromuscular deficits presumed by Darley, Aronson, and Brown (DAB)<sup>27-29</sup> to underlie ataxic dysarthria. In general, they include inaccurate movements, slow movements, and hypotonia of affected muscles. As a result, individual and repetitive movements contain errors in timing, force, range, and direction, and they tend to be slow and often irregular. The relationships among these characteristics and the specific deviant characteristics associated with ataxic dysarthria are discussed as follows. Experimental support for the presumed underlying neuromuscular deficits, especially those that reflect the global impression of incoordination, are reviewed in the section on acoustic and physiologic findings.

### Clusters of Deviant Dimensions and Prominent Deviant Speech Characteristics

DAB<sup>28</sup> found three distinct clusters of deviant speech dimensions in their group of 30 patients with cerebellar disorders. These clusters are useful to under-

**table 6-1** Neuromuscular deficits associated with ataxic dysarthria

Direction		Rhythm		Rate		Range		Force	Tone
Individual Movements	Repetitive Movements	Individual Movements	Repetitive Movements	Individual Movements	Repetitive Movements	Individual Movements	Repetitive Movements	Individual Movements	Muscle Tone
Inaccurate	Irregular	Slow	Slow	Excessive to normal	Excessive to normal	Normal to excessive			Reduced

Modified from Darley FL, Aronson AE, Brown JR: Differential diagnostic patterns of dysarthria, *J Speech Hear Res* 12:246, 1969.

**table 6-2** Clusters of abnormal speech characteristics in ataxic dysarthria

Cluster	Speech Characteristics
Articulatory Inaccuracy	Imprecise consonants Irregular articulatory breakdowns Distorted vowels
Prosodic Excess	Excess & equal stress Prolonged phonemes Prolonged intervals Slow rate
Phonatory-Prosodic Insufficiency	Harshness Monopitch Monoloudness

Modified from Darley FL, Aronson AE, Brown JR: Differential diagnostic patterns of dysarthria, *J Speech Hear Res* 12:246, 1969b.

standing the neuromuscular deficits that underlie ataxic dysarthria, the components of the speech system that are most prominently involved, and the features that distinguish ataxic dysarthria from other dysarthria types. These clusters are summarized in Table 6-2.

The first cluster is *articulatory inaccuracy*, represented by *imprecise consonants*, *irregular articulatory breakdowns*, and *vowel distortions*. These features reflect inaccuracy in the direction of articulatory movements and dysrhythmia of repetitive movements. They implicate movements of the jaw, face, and tongue primarily but do not exclude poorly controlled movements at the velopharyngeal or laryngeal valves.

The second cluster is *prosodic excess*, composed of *excess and equal stress*, *prolonged phonemes*, *prolonged intervals*, and *slow rate*. This cluster seems related to the slowness of individual and repetitive movements that are prominent in ataxia in general. DAB<sup>29</sup> noted that the slowing of repetitive movements seems to include "slowness, even metering of patterns, and excessive vocal emphasis on usually unemphasized words and syllables . . ." This cluster is probably related to descriptions of speech in individuals with cerebellar disease as *scanning* in character, a term defined in slightly different

ways by various authors.<sup>94,99</sup> It refers to slowness, a word-by-word cadence, syllable segregation, and relatively equal and obvious emphasis on each syllable or word whether normally stressed or unstressed (see Figure 6-3).

The third cluster is *phonatory-prosodic insufficiency*, composed of *harshness*,\* *monopitch*, and *monoloudness*. DAB attributed this cluster to insufficient excursion of muscles (presumably laryngeal and, possibly, respiratory) as a result of hypotonia.

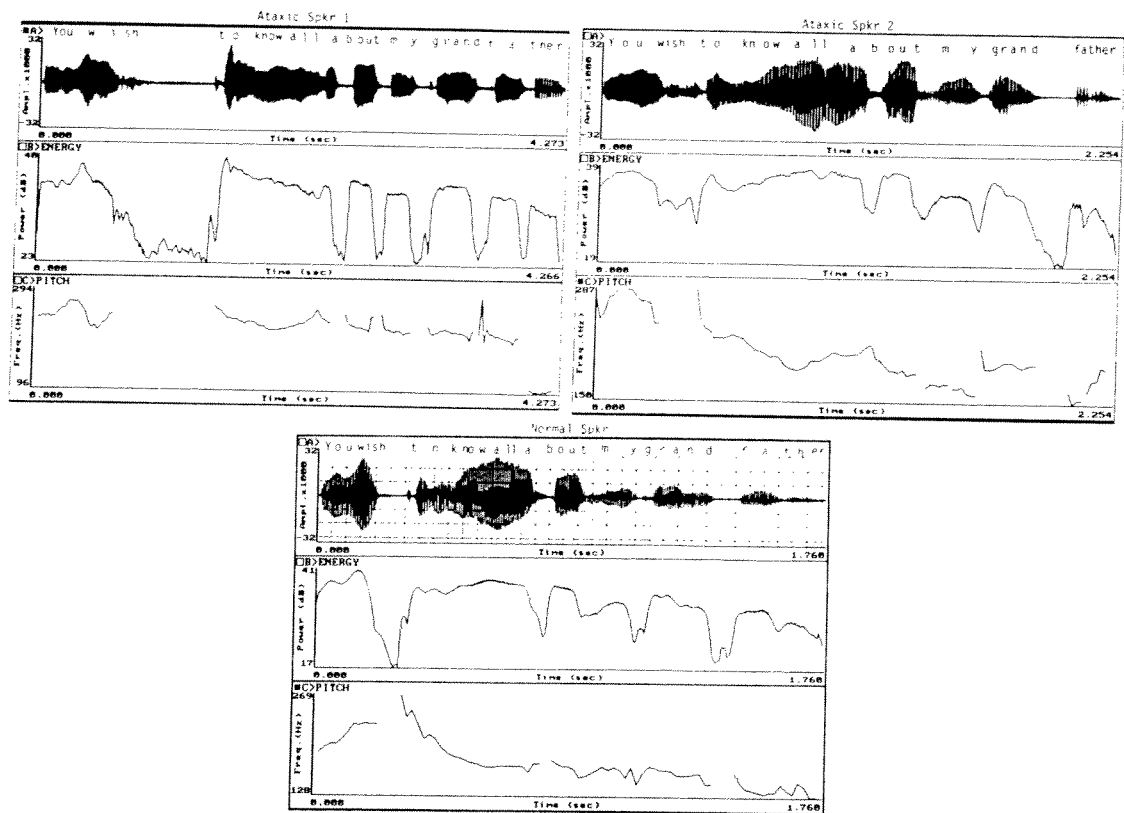
Table 6-3 summarizes the most deviant speech dimensions found by DAB.<sup>27</sup> The component of the speech system most prominently associated with each characteristic is also included. The rankings in the table represent the order of prominence (severity) of the speech characteristics and not necessarily the features that best distinguish ataxic dysarthria from other dysarthria types.<sup>†</sup>

A few additional comments are warranted about some of the clusters and prominent speech characteristics, because they are relevant to clinical diagnosis. These are based on some data embedded within those presented by DAB<sup>27,28</sup> or reflect clinical impressions from assessments of many patients with cerebellar disease.

1. The cluster of prosodic excess, particularly features of excess and equal stress and prolonged phonemes and intervals, although quite distinctive of ataxic dysarthria, is not prominent in all patients. For example, only 20 to 24 of DAB's 30 subjects with cerebellar

\*Although harshness was among the most deviant characteristics noted by DAB, in the author's experience it does not seem to occur frequently or be more than mildly evident in people with isolated ataxic dysarthria. In general, the presence of significant harshness in someone with ataxic dysarthria should raise questions about an accompanying spastic component.

†Kent et al.<sup>62</sup> point out that descriptions of the salient features of ataxic dysarthria are quite similar across different languages and dialects. In the author's experience, ataxic dysarthria (and other types) often can be recognized without difficulty in languages with which a clinician has little knowledge, simply on the basis of perceptual judgments of speech AMRs, vowel prolongation, and rate and prosodic features of conversational speech.



**FIGURE 6-3** Raw waveform and energy and pitch ( $f_0$ ) tracings for the sentence “You wish to know all about my grandfather” by a normal female speaker (*bottom tracings*) and two females with ataxic dysarthria (*upper tracings*). The normal speaker completes the sentence in less than 2 seconds with normal variability in syllable duration and amplitude (*energy tracing*) and normal variability and declination in  $f_0$  across the sentence (*pitch tracing*). Ataxic Speaker 1 is slow ( $\approx 4.3$  seconds for the utterance). Note also the relatively equal amplitude and duration of syllables for “. . . about my grandfather” in the energy tracing and the relative absence of  $f_0$  variability and declination in the pitch tracing. These represent acoustic correlates of the slow rate, excess and equal stress, and monoloudness and monopitch that are often apparent in ataxic dysarthria.

Ataxic Speaker 2 is not dramatically slow, and the energy and pitch tracings are grossly similar to the normal speaker’s. Note, however, that the word “grandfather” is produced more rapidly, particularly the syllables for “father”: the stressed syllable “fa” is shorter than the unstressed “ther” (*energy tracing*). These alterations are associated with perceivable breakdowns in articulation, as well as dysprosody characterized by abnormal stress and syllable durations.

- disease exhibited the speech features of this cluster. This lack of pervasiveness is not simply a function of severity because some patients with marked ataxic dysarthria and decreased intelligibility do not have prominent prosodic excess. In such cases it may be the cluster of articulatory inaccuracy that predominates, with irregular articulatory breakdowns giving speech an “intoxicated,” irregular character rather than a measured quality.
2. Relatedly, not all patients with ataxic dysarthria have irregular speech AMRs, even though irregular AMRs are a distinctive and fairly pervasive marker of the disorder. It is the author’s impression that irregular AMRs occur less frequently in patients with prominent prosodic excess (whose AMRs may be quite slow) and are more prominent in those with significant irregular articulatory breakdowns. Of course, many patients with ataxic dysarthria have both prosodic excess and articulatory inaccuracy.
  3. Irregular articulatory breakdowns are sometimes associated with *telescoping*, an occurrence that refers to an inconsistent breakdown of articulation in which a syllable or series of syllables are suddenly or unpredictably run together, giving speech a transient accelerated character.
  4. Some ataxic speakers exhibit *explosive loudness* and poorly modulated pitch and loudness variations. These characteristics do not appear within the most deviant characteristics

table

6-3

The most deviant speech dimensions encountered in ataxic dysarthria by Darley, Aronson, and Brown,<sup>27</sup> listed in order from most to least severe. Also listed is the component of the speech system associated with each characteristic. The component "prosodic" is listed when several components of the speech system may contribute to the dimension. Characteristics listed under "Other" include features not among the most deviant but that were judged deviant in a number of subjects and are not typical of most other dysarthria types.

<u>Dimension</u>	<u>Speech Component</u>
Imprecise consonants	Articulatory
Excess & equal stress*	Prosodic
Irregular articulatory breakdowns*	Articulatory
Distorted vowels*	Articulatory-prosodic
Harsh voice quality	Phonatory
Prolonged phonemes*	Articulatory-prosodic
Prolonged intervals	Prosodic
Monopitch	Phonatory-prosodic
Monoloudness	Phonatory-prosodic
Slow rate	Prosodic
Other	
Excess loudness variations*	Respiratory-phonatory-prosodic
Voice tremor	Phonatory

\*Tend to be distinctive or more severely impaired than in any other single dysarthria type.

or clusters of ataxic dysarthria, but they are striking when present. DAB observed excess loudness variability in one third of their subjects and noted that this feature is probably a component of what some have described as "explosive speech." Although it may not occur frequently, explosive loudness has traditionally been associated with cerebellar dysfunction.<sup>45</sup>

5. *Voice tremor* is not frequently encountered in ataxic dysarthria and does not emerge among the clusters of deviant speech characteristics or among its most deviant speech characteristics.<sup>27,28</sup> However, cerebellar disease can be associated with tremor of the laryngeal and respiratory muscles that results in a slow voice tremor of approximately 3 Hz.
6. Abnormal resonance is rare in ataxic dysarthria. However, intermittent *hyponasality* is perceived in some speakers. These infrequent occurrences presumably reflect improper timing of velar and articulatory ges-

tures for nasal consonants. Although uncommon, *intermittent hyponasality* is probably more frequently encountered in ataxic dysarthria than any other dysarthria type.

7. If some patients with ataxic dysarthria have predominant prosodic excess while others have predominant articulatory inaccuracy, if the two clusters can occur relatively independently, and if some patients with ataxic dysarthria truly have predominant explosive loudness, this means that *there may be subtypes of ataxic dysarthria*. If true, subtypes might be tied to differences in lesion location within the cerebellar control circuit, differences in the nature of the cerebellar disorder, or differences among speech subsystem impairments (findings relevant to the possibility of subtypes are reviewed in the next section).

What features of ataxic dysarthria help distinguish it from other MSDs? Among all of the abnormal speech characteristics that may be detected, *irregular articulatory breakdowns*, *irregular speech AMRs*, *excess and equal stress*, *excess loudness variations*, and *distorted vowels* are the most common distinctive clues to the presence of the disorder.

Table 6-4 summarizes the primary distinguishing speech characteristics and common oral mechanism examination findings and patient complaints associated with ataxic dysarthria.

## Acoustic and Physiologic Findings

### *Respiratory and Laryngeal Function*

The few physiologic investigations of respiration during speech in ataxic dysarthria make it clear that respiratory functions can be disturbed. Some early studies of a single or a few subjects found evidence of reduced vital capacity, incoordination between rib cage and abdominal movements, and incoordination between the timing of onset of respiration and phonation leading to air wastage.<sup>1,23</sup>

In a comprehensive study employing spirometric and kinematic techniques, Murdoch et al.<sup>83</sup> examined respiratory function during speech and nonspeech tasks in 12 people with cerebellar disease and ataxic dysarthria. Several differences were found between normal controls and a significant proportion of the ataxic speakers during vowel prolongation, syllable repetition, and reading and conversational tasks. The most salient findings for the ataxic speakers included: (1) reduced vital capacity, (2) paradoxical movements or abrupt changes in movements of the rib cage and abdomen, (3) irregularities in chest wall movements during sustained vowels and syllable repetition, and (4) a tendency to initiate utterances at

table

6-4

### Primary distinguishing speech and speech-related findings in ataxic dysarthria

<b>Perceptual</b>	
<b>Phonation-respiration</b>	Excessive loudness variations
<b>Articulation-prosody</b>	Irregular articulatory breakdowns Irregular AMRs Distorted vowels Excess & equal stress Prolonged phonemes
<b>Physical</b>	Dysmetric jaw, face, & tongue AMRs
<b>Patient Complaints</b>	"Drunk" or intoxicated speech Stumbling over words Biting tongue or cheek when speaking or eating Speech deteriorates with alcohol Poor coordination of breathing with speech

AMRs, Alternate motion rates.

lower than normal lung volume levels. These abnormalities seemed to reflect poor coordination of chest wall components of respiration, something the authors felt could explain some of the prosodic abnormalities perceived in ataxic speakers.

The existence of respiratory incoordination was confirmed by McClean, Beukelman, and Yorkston,<sup>79</sup> who examined the ability of an ataxic speaker to track a visually presented sinusoidal target by controlling respiratory movements. The subject's control of respiratory movements bore only a limited relationship to target movements, and there was marked variability in performance. The subject was also unable to vary fundamental frequency ( $f_0$ ) to perform the tracking task (normal speakers and some individuals with other dysarthria types could), suggesting that the task's demands far exceeded the subject's motor control ability.

DAB<sup>29</sup> summarized a number of early acoustic studies that bear on the issue of laryngeal speech control.<sup>46,53,70,94</sup> In general, studies suggest that patients with cerebellar involvement may display "restricted pitch and intensity variability, and individual patterns of aberrant vocal fold vibration that may be related to perceived voice quality deviations or may precede the development of audible changes in voice."<sup>29</sup> DAB pointed out that what might be perceived as phonatory abnormalities could also be the result of dysfunction at the respiratory level.

Subsequent studies support the frequent clinical perception of unsteadiness during vowel prolongation and frequent instability of pitch and loudness within connected speech. That is, acoustic studies of

varying numbers of people with various cerebellar diseases who presumably had ataxic dysarthria often report (in varying proportions of those tested) increased rather than decreased variability on several measures of long-term and short-term phonatory stability.<sup>39,40,61,65</sup> These abnormalities have generally been identified on vowel prolongation tasks but have sometimes been derived from AMR and sentence-level tasks. They include abnormal variability in long-term measures of  $f_0$  and intensity,<sup>39,61,63</sup> increased jitter and shimmer values,<sup>7,63</sup> increased pitch level,<sup>7</sup> harshness,<sup>61</sup> and abnormal voice onset time (VOT) values (see next section for details). These abnormalities have been reported in men and women, but occasional gender differences have been observed; for example, Kent et al.<sup>63</sup> found a high occurrence of abnormal shimmer values for female but not male ataxic speakers.

Although voice tremor is only infrequently evident in ataxic dysarthria, it has been confirmed by acoustic analysis in some speakers.<sup>6,7,20</sup> For example, Ackermann and Ziegler<sup>6</sup> found a 3-Hz voice tremor in a woman with chronic cerebellar atrophy with an ataxic dysarthria and voice tremor; respiratory and articulatory tremor were ruled out, because rhythmic oscillations were not present during sustained voiceless fricatives. This tremor rate is consistent with other forms of cerebellar postural tremor. It is of interest that Kent et al.<sup>63</sup> found that a rate of approximately three syllables per second often occurred during AMR, sentence repetition, and conversation tasks, corresponding to the frequency of cerebellar tremor. The authors speculated that tremor rate may serve "as an attractor for syllable tempo," possibly explaining the tendency toward uniform syllable duration and equal stress in conversation; that is, the tremor may serve as a temporal substrate for voluntary movements, with temporal irregularities arising "because of inaccuracies in muscle activation (e.g., variant contraction times in the musculature) or intersystem incoordination."

Taken together, these abnormalities suggest that ataxic dysarthria, at least in some individuals, is characterized in part by *phonatory instability* or *phonatory-respiratory instability*. The explanations for this instability most often point to problems of coordination, timing, or control. For example, Ackermann and Ziegler<sup>6,7</sup> speculated that asymmetrically distributed motor deficits at the laryngeal level and altered sensory (e.g., proprioceptive) control of laryngeal or respiratory reflexes could account for impaired control of tension in intrinsic laryngeal muscles, leading to phonatory instability.

\*Kent et al.<sup>61</sup> noted that long-term measures of  $f_0$  and amplitude variability might be particularly sensitive indices of phonatory dysfunction in ataxic dysarthria, and MSDs in general.

In addition, voicing errors imply poor laryngeal control or laryngeal-supraglottic timing errors.<sup>61</sup>

### Articulation, Rate, and Prosody

A number of acoustic and physiologic studies support, quantify, and help explain the clinical perception of slow rate, irregular articulatory breakdowns, and prosodic abnormalities in ataxic dysarthria.

Various acoustic analyses have documented *slow rate* on AMR tasks and during word and sentence production.<sup>84</sup> Slowness of movement in ataxic speech has also been demonstrated in a cineradiographic study of articulatory movements<sup>58</sup> and in a kinematic study of lower lip movements during speech.<sup>5,9</sup>

Slowness during connected speech in ataxic dysarthria includes longer sentence and syllable durations, longer formant transitions, lengthened consonant clusters and vowel nuclei in words and syllables, and, sometimes, longer VOT.<sup>10,25,49,57,59,61,72</sup> There also is evidence that some ataxic speakers have difficulty changing speech rate or producing faster speech rates,<sup>40,61</sup> suggesting that slow rate is not just, or not always, compensatory.

It is reasonable to ask if slow rate might predict intelligibility or severity in ataxic dysarthria. It appears this may not be the case. Although Ziegler and Wessel<sup>105</sup> found that maximum AMR rate was a good predictor of severity and intelligibility, Kent et al.<sup>63</sup> found that AMR rate was not correlated with perceived overall severity of dysarthria during conversation. In addition, Linebaugh and Wolfe<sup>72</sup> found no relationship between duration and measures of intelligibility or naturalness. These latter findings support general clinical observations that intelligibility can be quite good in some speakers whose rate is slow. They also support the clinical impression that *speech characteristics or speaking tasks that may be sensitive to the presence and type of a disorder do not necessarily predict intelligibility or other ratings of severity.*

What is the basis for slow rate? Hypotonia has been offered as one explanation.<sup>25,40,49,58</sup> That is, the reduced tone and muscular tension that characterize hypotonia may delay the generation of muscle force and reduce the rate of muscle contraction, with resultant slowness of movement and prolongation of sounds.<sup>58</sup> Another explanation is that cerebellar damage—because it may interfere with the cerebellum's role in revising provisional cortical motor

commands—may lead to a heavier reliance on basic cortical motor programs for movement control. Because cortical revisions of a motor program presumably take longer than cerebellar revisions, speech segment durations might be increased to allow time for the longer and slower cortical loops to operate.<sup>9,25,59</sup> This explanation is intriguing, and it raises questions about whether imposition of cortical control in response to cerebellar damage occurs “automatically,” is dependent on the specific nature of the cerebellar deficit, reflects an intentional compensatory response by the speaker, or represents a combination of these possibilities. The outcome in any case would be a slowing of speech rate.

In addition to slow rate—and more relevant to the truly distinctive perceptual characteristics of ataxic dysarthria—acoustic and physiologic studies have frequently documented and sometimes specified the parameters of *abnormalities in rhythm on speech AMR tasks*.<sup>\*</sup> The sensitivity of the AMR task to timing problems confirms its usefulness in the perceptual and acoustic assessment of the disorder (see Figure 6-2). The loci of increased variability in AMRs have included VOT, vowel duration, syllable gaps, and minimum and maximum energy values.<sup>61,63</sup> Irregularities in chest wall movements during speech AMRs have also been documented kinematically in some ataxic speakers.<sup>183</sup> All of these findings, plus others discussed later, speak to the presence of *timing problems* in the disorder. Kent et al.<sup>61</sup> concluded that *temporal dysregulation* is a primary component of ataxic dysarthria and that its effects “are most evident in the production of longer syllabic strings, even if they take the form of simple syllable repetition,” suggesting that the cerebellum may have a major role in regulating precise timing during long or complex sequences of motor activity.

Timing abnormalities are also evident in measures of VOT, which are felt to be a sensitive index of laryngeal control or laryngeal-articulatory coordination. Abnormal VOT values are found frequently in ataxic speakers.<sup>3,25,59,61</sup> They include shorter than normal VOT, longer than normal VOT, and overlapping or more variable than normal VOT across repeated responses,<sup>25,59,61</sup> all which suggest abnormal variability beyond that explainable by general slowness. The

\*References 4, 19, 39, 40, 50, 59, 61, 63, 88, 96, 104, 105.

<sup>183</sup>These irregularities within the speech system are not necessarily unique to speech. For example, McNeil et al.<sup>80</sup> studied isometric force and static position control of the upper and lower lip, tongue, and jaw during nonspeech tasks in four ataxic speakers. They had greater force and position instability than normal speakers. McClean, Beukelman, and Yorkston's<sup>79</sup> ataxic speaker performed poorly on a nonspeech visuomotor tracking task involving the lower lip and jaw.

<sup>84</sup>The work of Kent and Netsell<sup>58</sup> is an excellent example of how inferences derived from acoustic and physiologic studies can lead to refinements or modifications of hypotheses generated by perceptual analyses of the dysarthrias.

<sup>105</sup>References 2, 4, 19, 32, 39, 40, 48, 57, 58, 59, 61, 86, 88, 96, 104, 105.



finding of Kent et al.<sup>61</sup> that the most frequent intelligibility errors in a group of ataxic speakers were related to voicing contrasts attests to the relevance of poor VOT control to some perceptual errors.

Several acoustic and aerodynamic studies have quantified and determined the loci of problems with stress and prosody at the word and sentence level (see Figure 6-3). They lend further support to conclusions that problems with timing, coordination, and control are common in the disorder. Markedly abnormal fluctuations in  $f_0$  and intensity, restriction of  $f_0$  variation, excessive interword pauses, irregularity of segment durations, and apparent increased articulatory effort (as reflected in peak intraoral air pressure) have been documented.<sup>24,40,58,84,102</sup> Aberrations in speech segment duration with increased length of utterance were documented by Kent, Netsell, and Abbs,<sup>59</sup> who found that the normal tendency to reduce base word duration as the number of syllables in words increases was inconsistent in ataxic speakers. For example, the duration of the syllable "please" in the sequence "please, pleasing, pleasingly" showed inconsistent reductions, small reductions, and occasional lengthening of the base word as the number of syllables increased. Although lengthened segments (slow rate) seemed characteristic of the ataxic speakers, inconsistent degrees of lengthening altered speech stress and timing patterns. Lax and unstressed vowels were more likely to be disproportionately lengthened, a finding that fits well with the perception of excess and equal stress or *scanning* in some speakers. The authors speculated that ataxic speakers do not decrease syllable duration when it is appropriate, because such reductions require flexibility in sequencing complex motor instructions. The lack of flexibility may lead to a syllable-by-syllable motor control strategy with subsequent abnormal stress patterns.

Problems of stress and prosody identified in instrumental studies clearly have perceptual salience. For example, Liss et al.<sup>74</sup> found that listeners transcribing ataxic speech had difficulty distinguishing strong and weak syllables, even when they had been familiarized with ataxic speech, and even though their intelligibility scores improved with familiarization. Listeners also seem to have difficulty determining lexical boundaries in speakers with ataxic dysarthria, partly as a function of abnormalities in speech rhythm.

The apparent coexistence of the clusters of prosodic excess and phonatory-prosodic insufficiency in ataxic dysarthria (as established by DAB) is curious, because they seem to be mutually exclusive abnormalities. Observations and analysis of this paradoxical relationship seem to confirm the presence of both problems in the disorder, although whether they coexist within the same patient is not quite so clear. Across patients, acoustic studies have

identified both excessive and reduced variability of speech segment durations.<sup>2,39,40,59,61</sup> The existence of scanning (prosodic excess) has been documented in acoustic studies,<sup>48,60,95</sup> with its specific acoustic characteristics represented by limited variation in syllable duration, fairly regular spacing between syllabic nuclei, and a generally flat  $f_0$  contour. In general, these features are consistent with "an equalization across syllables with respect to their prosodic content."<sup>60</sup> Thus in the scanning speech of ataxic dysarthria, variability of segment durations and  $f_0$  may actually be less than normal, a seeming contradiction to many findings of variability that have already been discussed.

Hartelius et al.<sup>48</sup> offered an explanation for this paradox. Their 14 ataxic speakers had longer than normal syllable durations and less variability (more *isochrony*, or syllable equalization) in their production of consecutive syllables within sentences, a pattern suggestive of *inflexibility*. However, they also had increased variability of syllable duration across repetitions of the same sentence, as well as increased variability of interstress intervals (i.e., the intervals between stressed vowels within sentences); these characteristics suggest *instability*. The authors felt that this cooccurrence of both inflexibility and instability of temporal control could explain the apparently contradictory perceptual characteristics of prosodic excess and phonatory-prosodic insufficiency.

Is prosodic excess more prominent or important than phonatory-prosodic insufficiency or articulatory inaccuracy to the diagnosis and understanding of ataxic dysarthria? Although Ackermann et al.<sup>8</sup> emphasized irregular articulatory breakdowns as the core speech disturbance, as opposed to scanning or prosodic excess, this does not always seem to be the case clinically. It seems possible that the apparent paradoxical cooccurrence of prosodic excess and articulatory inaccuracy (particularly irregular articulatory breakdowns) might reflect individual differences. That is, if subtypes of ataxic dysarthria exist, they could reflect differences in the degree to which inflexibility versus instability of motor control predominate, leaving some affected people with predominant prosodic insufficiency and articulatory inaccuracy, others with predominant problems of excess stress, and others with a more equal combination of the two.

There is some acoustic evidence that suggests subgroups of ataxic dysarthria do exist, although not along the lines just discussed. Subgroups have been identified as a function of variability in the temporal characteristics and intensity of speech AMRs, with differences in variability among subgroups possibly reflecting different subsystem impairments<sup>19</sup> but not necessarily differences in the nature of the cerebellar disorder.<sup>63</sup> Boutsen, Bakker, and Duffy<sup>19</sup> identified three subgroups from among a group of 27 ataxic

speakers. One group had similar durational variability among AMRs for "puh," "tuh," and "kuh." For the other two groups durational variability was dependent on the specific syllable. These differences were not related to severity or etiology, and they raised the possibility of different subsystem impairment. The authors concluded, "ataxic dysarthria may not be a unitary disorder in which differences among patients' speech characteristics are simply a function of

dysarthria severity." Relatedly, Kent et al.<sup>62</sup> suggested that global effects related to temporal dysregulation and positioning errors may be common to all patients with the disorder, whereas other abnormalities might be variable across patients and reflect specific impairments in different muscle systems.

The general observations derived from acoustic and physiologic studies reviewed in this section are summarized in Table 6-5.

table

6-5

Summary of acoustic and physiologic findings in studies of ataxic dysarthria. Note that many of these observations are based on studies of only one or a few speakers, and that not all speakers with ataxic dysarthria exhibit these features. These characteristics are not necessarily unique to ataxic dysarthria; some may also be characteristic of other motor speech disorders, or nonneurologic conditions.

<u>Speech Component</u>	<u>Acoustic or Physiologic Observation</u>
<b>Respiratory or Laryngeal</b>	<ul style="list-style-type: none"> <li>Abnormal &amp; paradoxical rib cage &amp; abdominal movements</li> <li>Irregularities in chest wall movements</li> <li>Initiation of utterances at reduced lung volume levels</li> <li>Reduced vital capacity (probably secondary to incoordination)</li> <li>Poor visuomotor tracking with respiratory movements &amp; <math>f_0</math></li> <li>Increased long-term variability of <math>f_0</math> &amp; peak amplitude during vowel prolongation &amp; AMRs</li> <li>Increased shimmer &amp; jitter</li> <li>Voice tremor (<math>\approx 3</math> Hz)</li> </ul>
<b>Articulation, Rate, and Prosody</b>	<ul style="list-style-type: none"> <li>Reduced rate:               <ul style="list-style-type: none"> <li>Increased syllable &amp; sentence duration</li> <li>Increased duration of formant transitions</li> <li>Longer VOT (but sometimes shorter)</li> <li>Lengthened consonant clusters &amp; vowel nuclei</li> <li>Slow AMRs</li> <li>Disproportionate lengthening of lax or unstressed vowels</li> <li>Excessive interword pauses</li> <li>Difficulty initiating purposeful movement</li> <li>Slow lip, tongue, &amp; jaw movements</li> <li>Difficulty increasing speech rate</li> </ul> </li> <li>Increased variability, inconsistency, or instability of:               <ul style="list-style-type: none"> <li>Segment durations</li> <li>Rate</li> <li>Intensity (maximum &amp; minimum energy values)</li> <li>AMR rate &amp; intensity</li> <li><math>f_0</math></li> <li>VOT</li> <li>Range &amp; velocity of articulatory movements, especially AMRs</li> <li>Inconsistent reduction of base word (first syllable) duration as number of syllables in words increases</li> <li>Inconsistent velopharyngeal closure</li> </ul> </li> <li>Reduced variability or restriction of:               <ul style="list-style-type: none"> <li>Anterior-posterior tongue movements during vowel production</li> <li>Syllable duration</li> <li>Spacing between syllabic nuclei</li> <li><math>f_0</math> contour in connected speech</li> </ul> </li> <li>Other:               <ul style="list-style-type: none"> <li>Breakdown in rhythmic EMG patterns in articulatory muscles during syllable repetition</li> <li>Poor visuomotor tracking with lower lip &amp; jaw movements on nonspeech tasks</li> <li>Increased instability of force &amp; static position control in lip, tongue, &amp; jaw on nonspeech tasks</li> <li>Occasional failure of articulatory contact for consonants.</li> </ul> </li> </ul>

## Cases

### Case 6-1

A 41-year-old woman presented for speech evaluation before neurologic assessment. She had been aware of a change in her speech for approximately a year, and people frequently asked if she was "on drugs or drinking." Speech deteriorated under conditions of stress or fatigue, but she felt intelligibility remained normal. She denied chewing or swallowing difficulty. She mentioned that her 49-year-old brother also had gait, balance, and speech difficulties.

Oral mechanism examination was normal in size, strength, and symmetry. Gag reflex was hypoactive. Cough and glottal coup were normal. Snout, sucking, and jaw jerk reflexes were absent.

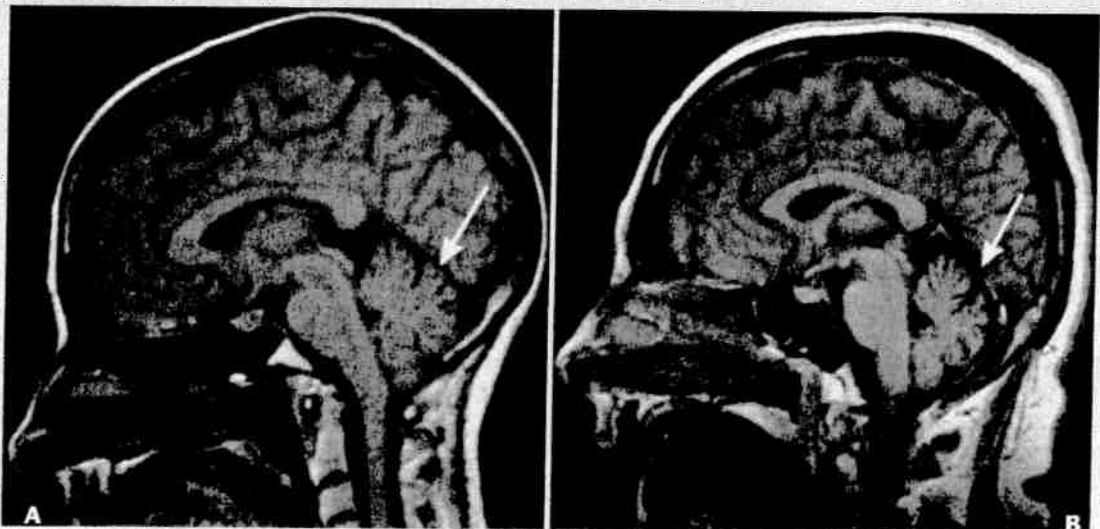Conversational speech was characterized by irregular articulatory breakdowns (1,2), reduced rate (1,2), dysprosody (1), occasional excess and equal stress (0,1), reduced pitch (0,1), and nonspecific subtle hoarseness (0,1). Speech AMRs were slow and irregular (1,2). Prolonged "ah" was unsteady (1). Speech intelligibility was normal.

The clinician concluded, "ataxic dysarthria, relatively mild." Both the patient and clinician felt therapy

was unnecessary, but she was advised to pursue reassessment and therapy if her speech difficulties progressed.

Neurologic evaluation identified multiple signs of cerebellar involvement, particularly pronounced gait and balance difficulties. Computed tomography (CT) scan and magnetic resonance imaging (MRI) identified marked cerebellar atrophy (Figure 6-4) involving both cerebellar hemispheres and the vermis. Family history established that her brother and father probably had the same condition. It was suspected that the patient had an autosomal dominant cerebellar degenerative disease. Genetic counseling was provided; her three children were felt to have a one-in-two risk of inheriting cerebellar degenerative disease.

**Commentary.** (1) Ataxic dysarthria is a common and sometimes presenting sign of degenerative cerebellar disease, including inherited conditions. Its accurate diagnosis helps confirm disease localization. (2) Diagnosis of dysarthria and its specific type can be made even when the problem is mild and intelligibility is unaffected.



**FIGURE 6-4** Midsagittal magnetic resonance imaging demonstrating, **A**, normal adult brain structure and, **B**, mild to moderate cerebellar atrophy in a 54-year-old woman with degenerative cerebellar disease and mild ataxic dysarthria.

**Case 6-2**

A 27-year-old woman presented with a 10-year history of progressive gait imbalance, incoordination of the hands, and "slurred speech." Her symptoms worsened around her menstrual periods and when she was nervous or fatigued; they had worsened slightly during a pregnancy. Neurologic examination confirmed the presence of ataxic gait, upper limb ataxia, and nystagmus.

During speech examination, she admitted to an approximately 10-year history of "slurred speech," which did not seem to have progressed recently. Conversational speech was characterized by occasional irregular articulatory breakdowns (0,1), which were most apparent during consonant clusters and affricates. Infrequently, rate was mildly slowed and multisyllabic words were produced with excess and equal stress. Prolonged "ah" was unsteady (1). Speech AMRs were slow (1) but not noticeably irregular.

The clinician concluded that the patient had a "mild ataxic dysarthria" that was not pervasively apparent and did not affect intelligibility. Therapy was not recommended.

An electromyogram revealed a severe disorder of primary sensory neurons and other findings that were consistent with the diagnosis of spinocerebellar degeneration.

She was seen for follow-up 6 years later. There was some worsening of her gait disturbance but no worsening of her other deficits, including speech.

**Commentary.** (1) Ataxic dysarthria can be among the presenting signs of cerebellar degenerative disease. Its characteristics can be quite subtle, but its recognition can help confirm cerebellar dysfunction. (2) Some degenerative CNS diseases that affect speech may be so slowly progressive that intelligibility is preserved over many years.

**Case 6-3**

A 56-year-old woman presented for neurologic assessment with a primary complaint of speech difficulty. This had developed gradually, with some progression, over the previous 8 months. It was accompanied by general "awkwardness" when sewing or running and some memory problems. Neurologic examination was normal with the exception of her speech deficit, although questions were raised about depression and possible cognitive decline. Subsequent psychometric assessment was normal. CT and MRI scans were negative. A complete general medical workup was normal. Psychiatric consultation confirmed the presence of depression, probably developed in response to her neurologic or speech difficulties.

Speech examination was notable for the presence of irregular articulatory breakdowns during connected speech (2), irregular speech AMRs (2), and unsteadiness of vowel prolongation (1,2). Intelligibility was mild to moderately reduced. There was no evidence of aphasia.

The clinician concluded "dysarthria, ataxic (cerebellar), moderate-marked."

The neurologist concluded that the patient had a cerebellar dysarthria of undetermined etiology and stated that the underlying disease might "declare itself more clearly with time." She was seen approximately 18 months later for reassessment. Her dysarthria had worsened, and she had a clear-cut gait ataxia. MRI scan was again normal. Repeat psychometric assessment was unchanged, and no other abnormalities were identified during a complete medical workup. Again, the diagnosis was "cerebellar syndrome of unknown origin."

The patient experienced progression of her deficits over the next 18 months, but her only new symptom was a mild and vaguely described swallowing problem. These were reported through correspondence and not observed during formal reassessment. She was not seen for further follow-up.

**Commentary.** (1) Ataxic dysarthria can be the first and most prominent finding in degenerative neurologic disease. (2) It may precede the development of other signs of disease and may be present in the absence of neuroimaging evidence of cerebellar degeneration or lesions.

**Case 6-4**

A 63-year-old woman was hospitalized for evaluation and treatment of cardiovascular problems. She had a history of myocardial infarction and had had coronary bypass surgery 6 months previously. Three weeks before admission she developed the sudden onset of speech difficulty and problems with gait. She had no difficulties with language, chewing, or swallowing.

Oral mechanism examination was normal. Speech was characterized by irregular articulatory breakdowns (1,2), irregular speech AMRs (1), and unsteady vowel prolongation (2). Intelligibility was normal.

The clinician concluded that the patient had a "mild ataxic dysarthria." Because intelligibility was essentially normal, and because the patient was compensating well for her deficit and was generally unconcerned about it, therapy was not recommended.

Subsequent CT scan identified a 2-cm area of low attenuation in the right cerebellar hemisphere consistent with a diagnosis of stroke.

**Commentary.** (1) Ataxic dysarthria can result from cerebellar stroke and may be among the most prominent signs of such an event. (2) Although probably uncommon, ataxic dysarthria sometimes can result from a unilateral lesion affecting the cerebellar hemispheres. (3) Although some studies suggest that ataxic dysarthria resulting from unilateral cerebellar lesions occurs more frequently with lesions of the left cerebellar hemisphere, it can occur with lesions to the right cerebellar hemisphere. (4) The presence of dysarthria does not lead automatically to a recommendation for treatment. Such a recommendation is based on the degree of disability and the patient's judgment about, and compensations for, the problem, among other things.

**Case 6-5**

A 53-year-old woman presented with a 2- to 3-year history of intermittent "jumping" of her vision. For 9 months she had double vision, imbalance when walking, and mild "slurring" of speech, all of which had gradually worsened.

Neurologic examination revealed nystagmus, mild proximal weakness in all limbs, severe gait ataxia, and moderate limb ataxia. MRI scan revealed several areas of abnormality in the white matter of both hemispheres, suggestive of demyelinating disease. Multiple sclerosis was suspected, but she had a high cerebrospinal fluid white blood cell count. A serum Purkinje cell antibody test was ordered.

The patient felt that her speech was "slightly slurred." It had worsened over the past 5 months and was susceptible to fatigue. She sometimes bit her tongue when eating and occasionally drooled when laughing or crying.

The speech mechanism was normal in size, strength, and symmetry. Jaw and lateral tongue movements were dysmetric. Voluntary cough and glottal coup seemed poorly coordinated. Conversational speech was characterized by irregular articulatory breakdowns (3), dysprosody (3), excess and equal stress (scanning) (2,3), and inappropriate loudness variability (1). Overall speech rate was slow (-2). Speech AMRs were irregular (3) and slow (-2). Vowel prolongation was breathy and unsteady (1,2).

The speech clinician concluded, "Unambiguous, moderately severe ataxic dysarthria suggestive of cerebellar dysfunction. Unless she is emotionally upset while talking, speech intelligibility is good. In fact, the scanning quality to her speech works to her advantage in terms of intelligibility." Speech therapy was not recommended.

Subsequently, her serum Purkinje cell antibody test was positive, strongly suggestive of paraneoplastic cerebellar degeneration associated with underlying malignancy. She was unable to remain at the clinic for a full workup for malignancy, but this was pursued at home. Initial workups there were negative, but an ovarian tumor was discovered approximately 5 months later.

**Commentary.** (1) Ataxic dysarthria is not uncommon in cerebellar disease and frequently occurs in paraneoplastic syndromes that affect the cerebellum. In such cases, the dysarthria and other neurologic signs may be apparent before detection of the primary malignancy. (2) The presence of ataxic dysarthria (and other dysarthrias) does not dictate that therapy should be undertaken. The patient's intelligibility was normal, and there was nothing obvious about her speech that suggested therapy would alter speech in a direction of greater normalcy. She was advised to pursue therapy if her dysarthria worsened, however.

**Case 6-6**

A 49-year-old woman presented to neurology with a 1-year history of speech or balance difficulties and cognitive decline. She had also had three episodes of loss of consciousness. Hashimoto's thyroiditis was diagnosed approximately 6 months after the onset of her symptoms, and she subsequently underwent total thyroidectomy. Postoperatively, she was given a small dose of Synthroid.

Neurologic examination noted balance difficulty, speech difficulty, mental status problems, and apparent indifference to her symptoms. It was not certain if her problems were organic or nonorganic in nature.

During speech evaluation, she reported a 2-year history of episodic "garbled" speech with gradual progression to more constant difficulties. She also complained of occasional word retrieval difficulties and problems with spelling and recall. Oral mechanism examination was normal. Her speech pattern was somewhat unusual and included a moderate degree of hoarse-rough voice quality with occasional pitch breaks and unusual variability in pitch and duration. Irregular articulatory breakdowns were also evident. Rate was mildly slowed. Vowel prolongation was unsteady (+2). Speech AMRs were moderately irregular. There was no evidence of aphasic language impairment, but she occasionally

forgot stimuli and had to be re-instructed about the nature of tasks. The clinician concluded that the patient's speech problem was organic and that it represented an obvious ataxic dysarthria plus a mild dysphonia; it was noted that the dysarthria and dysphonia could be compatible with hypothyroidism. A recommendation regarding therapy was deferred until the completion of her medical workup.

The patient's electroencephalogram and MRI scan were normal. Assessment of thyroid function confirmed hypothyroidism, and thyroid hormone replacement medications were increased. She noted some improvement in all of her symptoms within several days, although she was advised that full benefit from the thyroid replacement treatment would take some time.

**Commentary.** (1) Ataxic dysarthria can be associated with hypothyroidism. (2) Dysarthria can be the first sign of neurologic disease, including neurologic signs and symptoms stemming from hypothyroidism. (3) Identification of dysarthria and its type can help establish if speech disturbances are compatible with certain neurologic conditions. Ataxic dysarthria and dysphonia are known possible sequences of hypothyroidism, whereas other MSDs typically are not.

**SUMMARY**

- Ataxic dysarthria results from damage to the cerebellar control circuit, most frequently damage to the lateral hemispheres or vermis of the cerebellum. It occurs at a frequency comparable to that for other major single dysarthria types. Although it may reflect deficits at all levels of speech production, it is most perceptible in articulation and prosody. Incoordination and reduced muscle tone appear responsible for the slowness of movement and inaccuracy in the force, range, timing, and direction of speech movements.
- Degenerative disease probably accounts for the largest proportion of cases of ataxic dysarthria; demyelinating, vascular, and undetermined etiologies are also common. Most patients have clinical evidence of cerebellar involvement other than ataxic dysarthria. When positive, neuroimaging studies frequently identify cerebellar lesions or abnormalities in the brainstem or posterior fossa.
- People with ataxic dysarthria frequently complain of slurred speech and a "drunken" quality to their speech. Complaints of dysphagia and difficulty with drooling are infrequent.
- The major clusters of deviant speech characteristics in ataxic dysarthria include articulatory inaccuracy, prosodic excess, and phonatory-prosodic insufficiency. Although many abnormal speech characteristics can be detected in ataxic dysarthria, irregular articulatory breakdowns, irregular speech AMRs, excess and equal stress, distorted vowels, and excess loudness variations are the most distinctive clues to the presence of ataxic dysarthria.
- In general, acoustic and physiologic studies of ataxic dysarthria have provided quantitative supportive evidence for the clinical perceptual characteristics of the disorder. They have helped to specify more completely the loci and dynamics of abnormal movements underlying the perceived speech disturbance. They support conclusions that slowness of movement and problems with timing are predominant deficits.
- Ataxic dysarthria can be the only, the first, or among the first or most prominent manifestations of neurologic disease. Its recognition and

correlation with cerebellar dysfunction can aid the localization and diagnosis of neurologic disease and may influence medical and behavioral management.

### References

1. Abbs JH, Hunker CJ, Barlow SM: Differential speech motor subsystem impairments with suprabulbar lesions: neurophysiological framework and supporting data. In Berry WR, editor: *Clinical dysarthria*. San Diego, 1983, College-Hill.
2. Ackermann H, Hertrich I: Speech rate and rhythm in cerebellar dysarthria: an acoustic analysis of syllable timing. *Folia Phoniatr Logop* 46:70, 1994.
3. Ackermann H, Hertrich I: Voice onset time in ataxic dysarthria. *Brain Lang* 56:321, 1997.
4. Ackermann H, Hertrich I, Hehr T: Oral diadokokinesis in neurological dysarthrias. *Folia Phoniatr Logop* 47:15, 1995.
5. Ackermann H, Hertrich I, Scharf G: Kinematic analysis of lower lip movements in ataxic dysarthria. *J Speech Hear Res* 38:1252, 1995.
6. Ackermann H, Ziegler W: Cerebellar voice tremor: an acoustic analysis. *J Neurol Neurosurg Psychiatry* 54:74, 1991.
7. Ackermann H, Ziegler W: Acoustic analysis of vocal instability in cerebellar dysfunctions. *Ann Otol Rhinol Laryngol* 103:98, 1994.
8. Ackermann H et al: Speech deficits in ischaemic cerebellar lesions. *J Neurol* 239:223, 1992.
9. Ackermann H et al: Kinematic analysis of articulatory movements in central motor disorders. *Mov Disord* 12:1019, 1997.
10. Ackermann H et al: Phonemic vowel length contrasts in cerebellar disorders. *Brain Lang* 67:95, 1999.
11. Adams RD, Victor M: *Principles of neurology*. New York, 1991, McGraw-Hill.
12. Amarenco P et al: Paravermal infarct and isolated cerebellar dysarthria. *Ann Neurol* 30:211, 1991.
13. Amici R, Avanzini G, Pacini L: *Cerebellar tumors: clinical analysis and psytopathologic correlations*. New York, Monographs in neural sciences, vol 4, Basel, Switzerland, 1976, Karger.
14. Anderson NE, Rosenblum MK, Posner JB: Paraneoplastic cerebellar degeneration: clinical-immunological correlations. *Ann Neurol* 24:559, 1988.
15. Aronson AE: *Clinical voice disorders*. New York, 1990, Thieme.
16. Baker KG et al: Neuronal loss in functional zones of the cerebellum of chronic alcoholics with and without Wernicke's encephalopathy. *Neuroscience* 91:429, 1999.
17. Barkovich AJ: *Pediatric neuroimaging*, ed 2. New York, 1995, Raven Press.
18. Barth A, Bogousslavsky J, Regli F: The clinical and topographic spectrum of cerebellar infarcts: a clinical-magnetic resonance imaging correlation study. *Ann Neurol* 33:451, 1993.
19. Boutsen FR, Bakker K, Duffy JR: Subgroups in ataxic dysarthria. *J Med Speech-Lang Pathol* 5:27, 1997.
20. Boutsen FR, Duffy JR: An analysis of tremor in ataxic dysarthria. Presented at the Conference on Motor Speech. Tucson, AZ, January 1998.
21. Brown JR: Localizing cerebellar syndromes. *JAMA* 141:518, 1949.
22. Brown JR, Darley FL, Aronson AE: Deviant dimensions of motor speech in cerebellar ataxia. *Trans Am Neurol Assoc* 93:193, 1968.
23. Brown JR, Darley FL, Aronson AE: Ataxic dysarthria. *Int J Neurol* 7:302, 1970.
24. Chester CS, Reznick BR: Ataxia after severe head injury. *Ann Neurol* 22:77, 1987.
25. Chiu MJ, Chen RC, Tseng CY: Clinical correlates of quantitative acoustic analysis in dysarthria. *Eur Neurol* 36:310, 1996.
26. Dalmau JO, Posner JB: Paraneoplastic syndromes. *Arch Neurol* 56:405, 1999.
27. Darley FL, Aronson AE, Brown JR: Clusters of deviant speech dimensions in the dysarthrias. *J Speech Hear Res* 12:462, 1969a.
28. Darley FL, Aronson AE, Brown JR: Differential diagnostic patterns of dysarthria. *J Speech Hear Res* 12:246, 1969b.
29. Darley FL, Aronson AE, Brown JR: *Motor speech disorders*. Philadelphia, 1975, WB Saunders.
30. Daube JR et al: *Medical neurosciences*. Boston, 1986, Little, Brown.
31. Diener HC, Dichgans J: Pathophysiology of cerebellar ataxia. *Mov Disord* 7:95, 1992.
32. Dworkin JP, Aronson AE: Tongue strength and alternate motion rates in normal and dysarthric subjects. *J Commun Disord* 19:115, 1986.
33. Dworkin LA et al: Cerebellar toxicity following high-dose cytosine arabinoside. *J Clin Oncol* 3:613, 1985.
34. Erdemoglu AK, Duman T: Superior cerebellar artery territory stroke. *Acta Neurol Scand* 98:283, 1998.
35. Espir MLE, Walker ME: Carbamazepine in multiple sclerosis. *Lancet* 1:280, 1969.
36. Evidente VG et al: Hereditary ataxias. *Mayo Clin Proc* 75:475, 2000.
37. Fadic R et al: Sensory ataxic neuropathy as the presenting feature of a novel mitochondrial disease. *Neurology* 49:239, 1997.
38. Fiez JA et al: Impaired non-motor learning and error detection associated with cerebellar damage. *Brain* 115:155, 1992.
39. Gentil M: Acoustic characteristics of speech in Friedreich disease. *Folia Phoniatr Logop* 42:125, 1990a.
40. Gentil M: Dysarthria in Friedreich's disease. *Brain Lang* 38:438, 1990b.
41. Gilchrist E, Wilkinson M: Some factors determining prognosis in young people with severe head injuries. *Arch Neurol* 36:355, 1979.
42. Gilman S, Bloedel JR, Lechtenberg R: *Disorders of the cerebellum*. Philadelphia, 1981, FA Davis.
43. Gilman S, Klün D: Perceptual analysis of speech disorders in Friedreich disease and olivopontocerebellar atrophy. In Bloedel JR et al, editors: *Cerebellar functions*. Berlin, 1984, Springer-Verlag.
44. Gironell A, Arboix A, Martí-Vilalta JL: Isolated dysarthria caused by a right paravermal infarction. *J Neurol Neurosurg Psychiatry* 61:205, 1996.
45. Grewel F: Classification of dysarthrias. *Acta Psychiatr Scand* 32:325, 1957.
46. Haggard MP: Speech waveform measurements in multiple sclerosis. *Folia Phoniatr Logop* 21:307, 1969.



47. Harding AE: Commentary: olivopontocerebellar atrophy is not a useful concept. In Marsden CN, Fahn S, editors: *Movement disorders 2*. New York, 1987, Butterworth.
48. Hartelius L et al: Temporal speech characteristics of individuals with multiple sclerosis and ataxic dysarthria: "scanning speech" revisited. *Folia Phoniatr Logop* 52:228, 2000.
49. Hertrich I, Ackermann H: Temporal and spectral aspects of coarticulation in ataxic dysarthria: an acoustic analysis. *J Speech Lang Hear Res* 42:367, 1999.
50. Hirose H et al: Analysis of abnormal articulatory dynamics in two dysarthric patients. *J Speech Hear Disord* 4:96, 1978.
51. Holmes G: Clinical symptoms of cerebellar disease. *Lancet* 2:59, 1922.
52. Jaekle KA, Cohen ME, Duffner PK: Primary and secondary tumors of the central nervous system: clinical presentation and therapy of nervous system tumors. In Bradley WG et al, editors: *Neurology in clinical practice: principles of diagnosis and management*, vol 2, ed 3. Boston, 2000, Butterworth-Heinemann.
53. Janvriin F, Worster-Drought C: Diagnosis of disseminated sclerosis by graphic registration and film tracks. *Lancet* 2:1348, 1932.
54. Joannette Y, Dudley JG: Dysarthric symptomatology of Friedreich's ataxia. *Brain Lang* 10:39, 1980.
55. Jordan JE: Thyroid disorder. *Semin Neurol* 5:304, 1985.
56. Judd LL: The therapeutic use of psychotropic medications. In Wilson et al, editors: *Harrison's principles of internal medicine*, New York, 1991, McGraw-Hill.
57. Kent R: Isovowel lines for the evaluation of vowel formant structure in speech disorders. *J Speech Hear Disord* 44:513, 1979.
58. Kent R, Netsell R: A case study of an ataxic dysarthric: cineradiographic and spectrographic. *J Speech Hear Disord* 40:115, 1975.
59. Kent RD, Netsell R, Abbs JH: Acoustic characteristics of dysarthria associated with cerebellar disease. *J Speech Hear Disord* 22:627, 1979.
60. Kent RD, Rosenbek JC: Prosodic disturbance and neurologic lesion. *Brain Lang* 15:259, 1982.
61. Kent RD et al: A speaking task analysis of the dysarthria in cerebellar disease. *Folia Phoniatr Logop* 49:63, 1997.
62. Kent RD et al: The dysarthrias: speech-voice profiles, related dysfunctions, and neuropathology. *J Med Speech-Lang Pathol* 6:165, 1998.
63. Kent RD et al: Ataxic dysarthria. *J Speech Lang Hear Res* 43:1275, 2000.
64. Kent RD et al: Clinicoanatomic studies in dysarthria: review, critique, and directions for research. *J Speech Lang Hear Res* 44:535, 2001.
65. Kent RD et al: Voice dysfunction in dysarthria: application of the Multi-Dimensional Voice Program. *J Commun Disord* 36:281, 2003.
66. Klein ES, Willbrand ML, Alvord LS: Cerebellar ataxia secondary to high-dose cytosine arabinoside (ARA-C) toxicity in treatment of acute leukemia: a case study. *J Med Speech-Lang Pathol* 7:243, 1999.
67. Kores B, Lader MH: Irreversible lithium toxicity: an overview. *Clin Neuropharmacol* 20:283, 1997.
68. Laforce R, Doyon J: Distinct contribution of the striatum and cerebellum to motor learning. *Brain Cogn* 45:189, 2001.
69. Lechtenberg R, Gilman S: Speech disorders in cerebellar disease. *Ann Neurol* 3:285, 1978.
70. Lehiste I: *Some acoustic characteristics of dysarthric speech*. Bibliotheca phonetica, fasc 2. Basel, Switzerland, 1965, Karger.
71. Liepert J et al: Reduced intracortical facilitation in patients with cerebellar degeneration. *Acta Neurol Scand* 98:318, 1998.
72. Linebaugh CW, Wolfe VE: Relationships between articulation rate, intelligibility, and naturalness in spastic and ataxic speakers. In McNeil MR, Rosenbek JC, Aronson AE, editors: *The dysarthrias: physiology, acoustics, perception, management*, San Diego, 1984, College-Hill Press.
73. Liss JM et al: Lexical boundary errors in hypokinetic and ataxic dysarthria. *J Acoust Soc Am* 107:3415, 2000.
74. Liss JM et al: The effects of familiarization on intelligibility and lexical segmentation in hypokinetic and ataxic dysarthria. *J Acoust Soc Am* 112:3022, 2002.
75. Logeman J: *Evaluation and treatment of swallowing disorders*, San Diego, 1983, College-Hill Press.
76. Manto M: Isolated cerebellar dysarthria associated with heat stroke. *Clin Neurol Neurosurg* 98:55, 1996.
77. Marien P, Engelborghs S, DeDeyn P: Cerebellar neurocognition: a new avenue. *Acta Neurol Belg* 101:96, 2001.
78. Mayo Clinic Department of Neurology: *Mayo Clinic examinations in neurology*, ed 7, St Louis, 1998, Mosby.
79. McClean MD, Beukelman DR, Yorkston KM: Speech-muscle visuomotor tracking in dysarthric and non-impaired speakers. *J Speech Hear Res* 30:276, 1987.
80. McNeil MR et al: Oral structure nonspeech motor control in normal, dysarthric, aphasic, and apraxic speakers: isometric force and static position. *J Speech Hear Res* 33:255, 1990.
81. Middleton FA, Strick PL: Basal ganglia and cerebellar loops: motor and cognitive circuits. *Brain Res Rev* 31:236, 2000.
82. Miller RM, Groher ME: *Medical speech pathology*, Rockville, Md, 1990, Aspen Publishers.
83. Murdoch BE et al: Respiratory kinematics in speakers with cerebellar disease. *J Speech Hear Res* 34:768, 1991.
84. Murry T: The production of stress in three types of dysarthric speech. In Berry W, editor: *Clinical dysarthria*. Boston, 1983, College-Hill Press.
85. Netsell R, Kent R: Paroxysmal ataxic dysarthria. *J Speech Hear Disord* 41:93, 1976.
86. Ozawa Y et al: Symptomatic differences in decreased alternating motion rates between individuals with spastic and with ataxic dysarthria: an acoustic analysis. *Folia Phoniatr Logop* 53:67, 2001.
87. Paslawski TM, Duffy JR, Vermino SA: Paraneoplastic cerebellar degeneration: a speech retrospective. Presented at the annual convention of the American Speech-Language-Hearing Association, November 2002.
88. Portnoy RA, Aronson AE: Diadochokinetic syllable rate and regularity in normal and in spastic ataxic dysarthria subjects. *J Speech Hear Disord* 47:324, 1982.

89. Putnam AHB: Review of research in dysarthria. In Winitz H, editor: *Human communication and its disorders, a review 1988*, Norwood, NJ, 1988, Ablex Publishing Corp.
90. Quinn N: Multiple system atrophy—the nature of the beast. *J Neurol Neurosurg Psychiatry Special Supplement*:78, 1989.
91. Ropper AH: The Guillain-Barré syndrome. *N Engl J Med* 326:1130, 1992.
92. Rossor MN: Dementia as part of other degenerative diseases. In Bradley WG et al, editors: *Neurology in clinical practice: principles of diagnosis and management*, vol 2, ed 3, Boston, 2000, Butterworth-Heinemann.
93. Rust RS: Neurocutaneous disorders. In Noseworthy JH, editor: *Neurological therapeutics: principles and practice*, vol 2, New York, 2003, Martin Dunitz.
94. Scripture EW: Records of speech in disseminated sclerosis. *Brain* 39:455, 1916.
95. Simmons N: Acoustic analysis of ataxic dysarthria: an approach to monitoring treatment. In Berry W, editor: *Clinical dysarthria*, Boston, 1983, College-Hill Press.
96. Tatsumi IF et al: Acoustic properties of ataxic and parkinsonian speech, in syllable repetition tasks. *Annu Bull Res Inst Logop Phoniatr* 13:99, 1979.
97. Trouillas P et al: International cooperative ataxia rating scale for pharmacological assessment of the cerebellar syndrome. *J Neurol Sci* 145:858, 1997.
98. von Cramon D: Bilateral cerebellar dysfunctions in a unilateral mesodiencephalic lesion. *J Neurol Neurosurg Psychiatry* 44:361, 1981.
99. Walshe F: *Diseases of the nervous system*, ed 11, New York, 1973, Longman.
100. Wood NW, Harding AE: Cerebellar and spinocerebellar disorders. In Bradley WG et al, editors: *Neurology in clinical practice: principles of diagnosis and management*, vol 2, ed 3, Boston, 2000, Butterworth-Heinemann.
101. Yorkston KM, Beukelman DR: Ataxic dysarthria: treatment sequences based on intelligibility and prosodic considerations. *J Speech Hear Disord* 46:398, 1981.
102. Yorkston KM et al: Assessment of stress patterning. In McNeil M, Rosenbek J, Aronson A, editors: *The dysarthrias: physiology, acoustics, perception, management*, Austin, Tex, 1984, Pro-Ed.
103. Yorkston KM et al: *Management of motor speech disorders in children and adults*, Austin, Tex, 1999, Pro-Ed.
104. Ziegler W: Task-related factors in oral motor control. *Brain Lang* 80:556, 2002.
105. Ziegler W, Wessel K: Speech timing in ataxic disorders. *Neurology* 47:208, 1996.